

Elsevier Editorial System(tm) for Medical Hypotheses

Manuscript Draft

Manuscript Number: YMEHY-D-06-00134R1

Title: Plaques of Alzheimer's disease originate from cysts of Borrelia Burgdorferi, the Lyme disease spirochete

Article Type: FLA Full Length Article

Section/Category:

Keywords:

Corresponding Author: Dr. Alan B. MacDonald, MD

Corresponding Author's Institution: St Catherine of Siena Medical Center

First Author: Alan B. MacDonald, MD

Order of Authors: Alan B. MacDonald, MD

Manuscript Region of Origin:

Plaques of Alzheimer's disease originate from cysts of *Borrelia burgdorferi*, the Lyme disease spirochete.

Alan B. MacDonald MD

St. Catherine of Siena Medical Center

Department of Pathology

50 Rte 25 A

Smithtown, New York

11787

USA

Telephone: 631-862-3764 (voice)

631-862-3863 (Fax)

email : inmacdonald@yahoo.com

Grant support: Turn the Corner Foundation, New York, New York

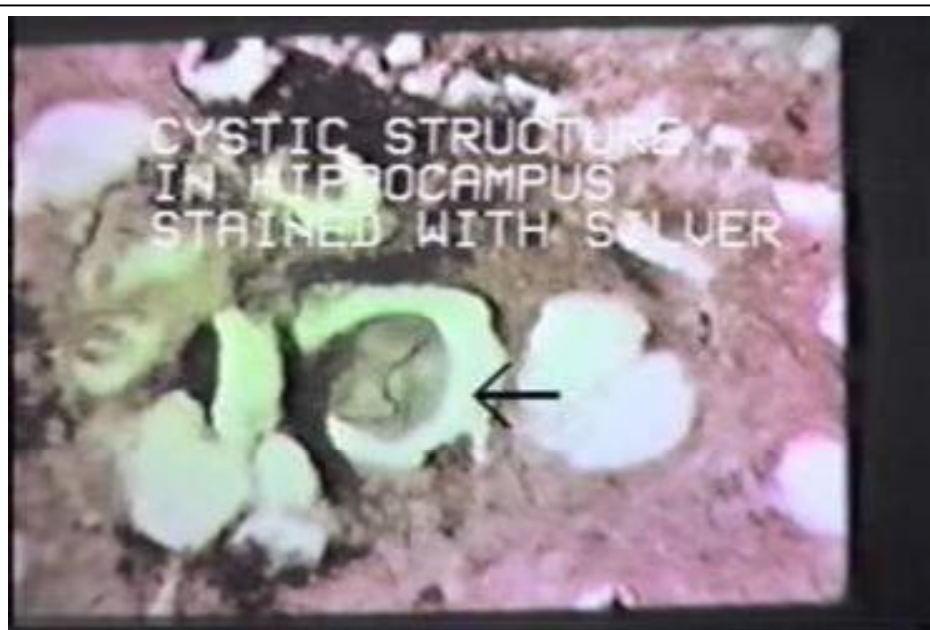Abstract:

Here is hypothesized a truly revolutionary notion that rounded cystic forms of *Borrelia burgdorferi* are the root cause of the rounded structures called plaques in the Alzheimer brain. Rounded "plaques" in high density in brain tissue are emblematic of Alzheimer's Disease (AD). Plaques may be conceptualized as rounded "pock mark-like" areas of brain tissue injury. In this century, in brain tissue of AD, plaques are **Amyloid Plaques** according to the most up to date textbooks. In the last century, however, Dr. Alois Alzheimer did not require amyloid as the pathogenesis for either the disease or for the origin of its plaques. Surely, amyloid is an event in AD, but it may not be the primal cause of AD. Indeed in plaques, amyloid is regularly represented by the "congophilic core" structure which is so named because the waxy amyloid material binds the congo red stain and *is congophilic*. However an accepted subset of plaques in AD is devoid of a congophilic amyloid core region, (these plaques "cotton wool" type plaques, lack a central congophilic core structure). Furthermore, there is "plaque diversity" in Alzheimer's. Small, medium and large plaques parallel variable cystic diameters for *Borrelia burgdorferi*. Perturbations of AD plaque structure (i.e. young plaques devoid of a central core and older plaques with or without a central core structure) offer room for an alternate pathway for explanation of ontogeny of the plaque structures. If amyloid is not required to initiate all of the possible plaques in Alzheimer's, is it possible that amyloid just a by product of a more fundamental primal path to dementia? If a byproduct status is assigned to amyloid in the realm of plaque formation, then is amyloid also an epiphenomenon rather than a primary pathogenesis for Alzheimer's disease. In the

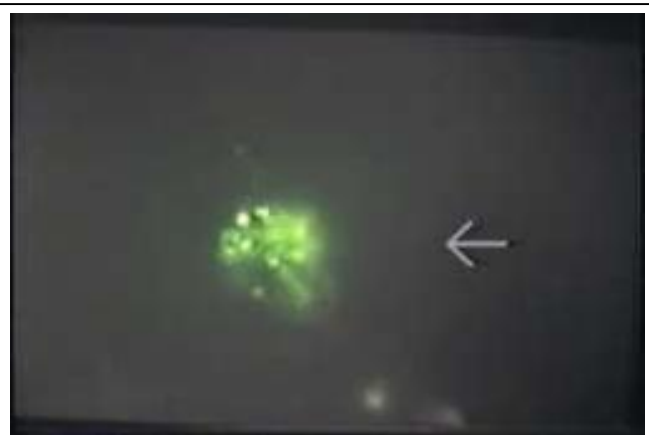“anatomy is destiny” model, cysts of borrelia are always round .Why then not accept roundness as a fundamental “structure determines function” argument for the answer to the mystery of why Alzheimer plaques are always round? Parataxis causality, a concept borrowed from philosophy, is the error that comes from linking two events, which occur contemporaneously or in close proximity to one another with a cause and effect relationship. Parataxis tells us that what appears to be cause and effect in the couplet “amyloid plaque” merely by a proximity relationship may be “spurious causality” which is a cognitive dead end.

Introduction:

The first published report of a cystic form for *Borrelia burgdorferi*, the etiologic agent of Lyme Borreliosis, was offered as a video poster presentation “Concurrent Neocortical Borreliosis and Alzheimer’s Disease – Demonstration of a Spirochetal Cyst Form”, at the International Conference on Lyme Disease and Related Disorders which was sponsored by the New York Academy of Sciences and the New York Department of Health on September 14-16, 1987. (1)

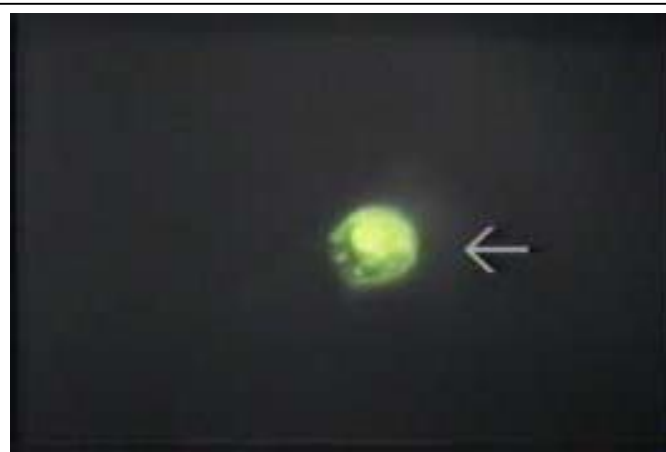

Cyst of *Borrelia* in Alzheimer brain tissue section stained with Krajian silver impregnation, 400x original magnification, this image from the Original video poster presented at the New York Academy of Sciences, 1987.



Cystic *Borrelia burgdorferi* from Alzheimer brain fingerprint with H9724 monoclonal Antibody 400x magnification. Note the internal structures within the cyst, some granular and others filamentous in profile.

Photograph date 1987.



**Cystic *Borrelia burgdorferi* in fingerprint monolayers from fresh Alzheimer autopsy brain tissue . (400x original magnification)
Fluorescence shows reactivity with protein epitopes specific for *Borrelia burgdorferi* and *B. hermsii*, murine monoclonal Antibody H9724, a gift from Alan G Barbour, MD.**

Photograph date 1987

Subsequently, beginning in 1994, published reports of cysts of *Borrelia burgdorferi* began to appear in the peer reviewed literature, and to date more than 40 articles from workers in Europe and the United States have ratified the scientific validity of rounded cystic forms of the spirochete emerging from the corkscrew forms under conditions of adversity (starvation, osmolar shock, acid pH, and antibiotic effects).(2.)

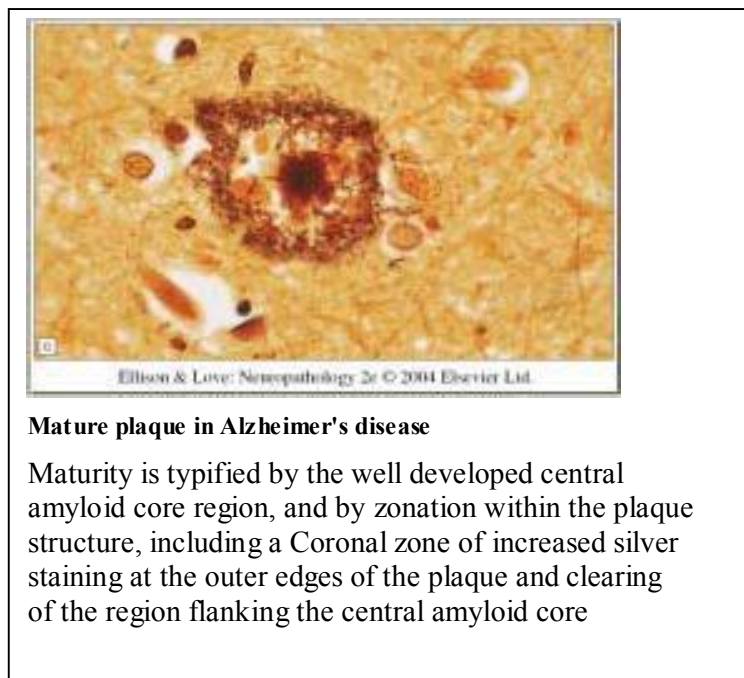
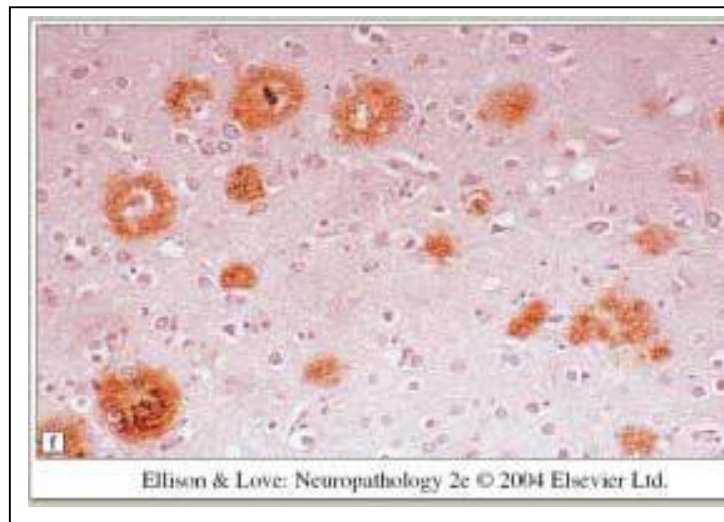Alzheimer's disease associated with corkscrew shaped *Borrelia* spirochetes in autopsy brain tissue has been reported by two pathologists,(3.,4,5,6) but cystic forms of *Borrelia burgdorferi* in Alzheimer brain tissues have only been the focus of research for one pathologist in the world. (7)

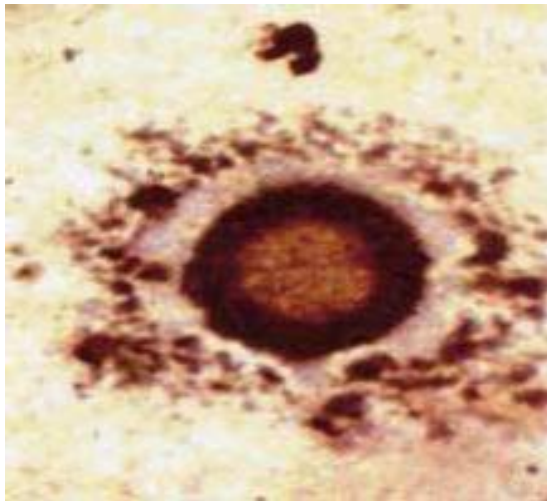
. Cystic profiles of borrelia closely correspond to the diverse profiles of plaques, namely they are always round, and are capable of increase in size from little to big as cystic spirochetal growth progresses. Maturation of cysts parallels "maturation" of plaques of increasing age, based on observations of spirochetal cysts in a tissue culture model. Cystic spirochetes in tissue culture incorporate injured cells into their interior regions. Amyloid fibrils within blood vessels of the brain may wind up within the plaque region, now redefined as spirochetal cyst "territory", merely because the rounded cyst "landed on a blood vessel" which contained amyloid in its wall. DNA hybridization methods demonstrate the areas where *Borrelia* DNA is deposited in the Alzheimer brain. Hybridizations using DNA from the spirochete develop a "map" of the terrain of the brain where, like little rounded villages and cities, rounded "map sites" of spirochetal DNA appear. Spirochetal sites on these "DNA maps" match the sites of the plaques in the

Alzheimer brain. .Now is the time for a new opportunity to re-evaluate Alzheimer's disease with DNA mapping methods.

The Hypothesis:

Cystic spirochetes show close structural similarities to the profiles of AD plaques. First, will be images of the plaques, second will be spirochetal cysts.



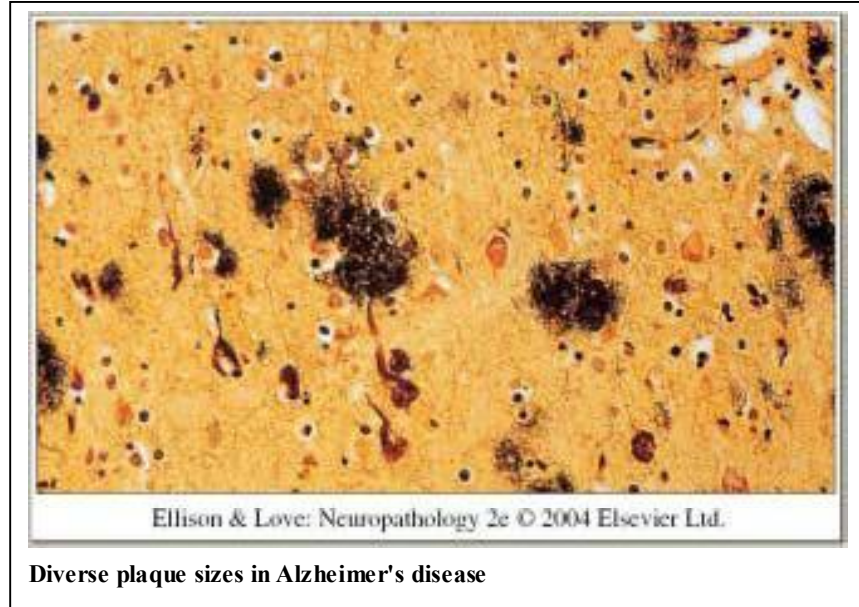


Cystic form of *Borrelia burgdorferi* stained with silver showing rounded contour and zonation within the center of the cyst. Pure culture of *Borrelia burgdorferi* from the American Type Culture collection, allowed to age for one year Magnification 1000x.

Year 1996

Therefore, the hypothesis was formulated that the cysts of the spirochete are the actual cause of the plaques.

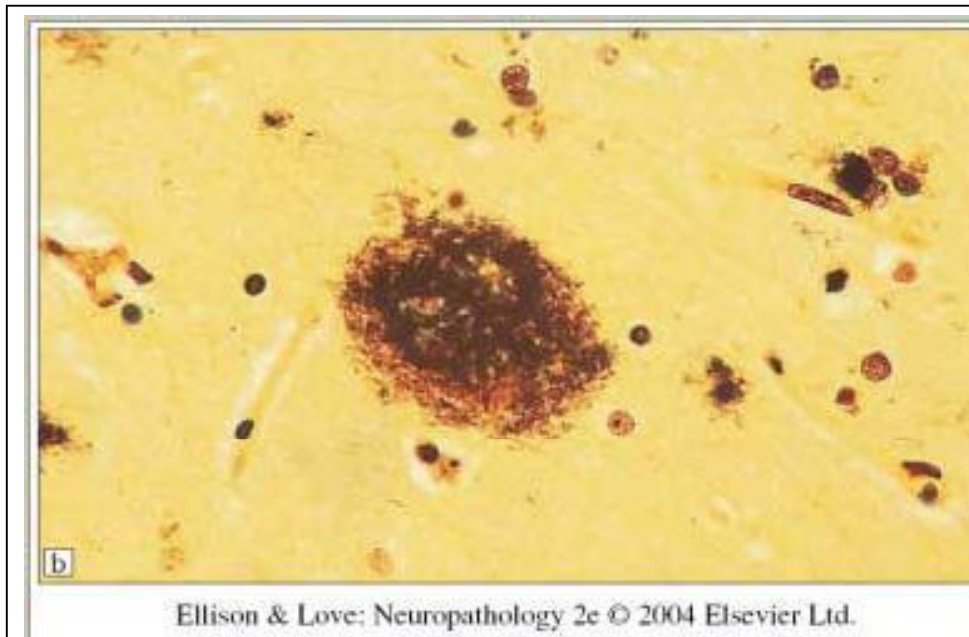
Currently, there is no iterated model to explain, in the absence of the cystic pathway to plaque formation in AD, a mechanism to define the facts that plaques in AD are virtually always round in contour, variable in diameter and separated by neural tissue that is “plaque free”, in the planes of histological section.



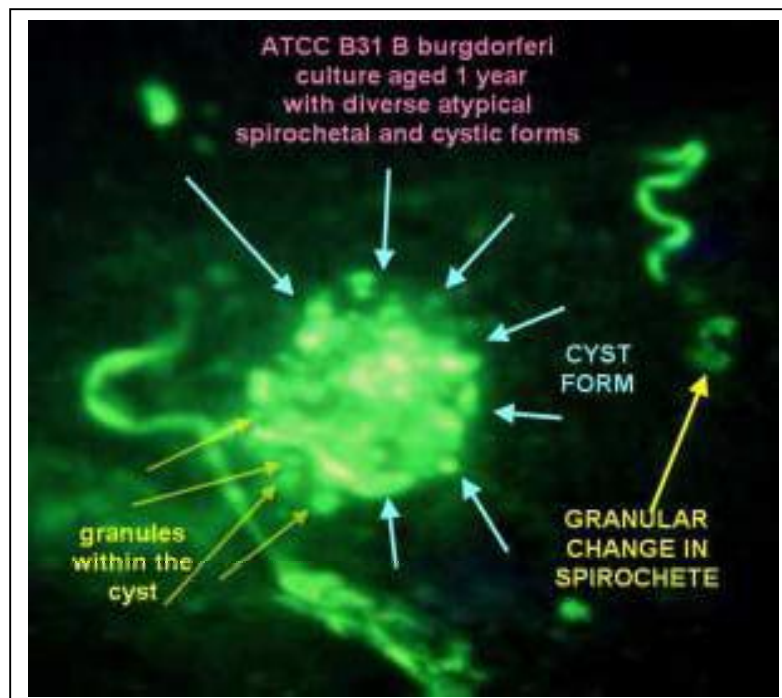
If “bad human DNA” is responsible for the origin of Plaques in AD, the chronology, topography, and ontogeny of plaques should be monotonous in image profiles, with all plaques emerging from a common morphology, and all plaques showing the same maturation sequence. In practice, plaques in AD are diverse in morphology and heterogeneous in maturation. (as would be expected in maturation of spirochetal cysts) Diversity and heterogeneity are the “stuff” of cystic spirochetes.

Cyst forms, intruded into brain tissue, as a consequence of chronic infection, would solve the puzzle of the origins of the plaques. Morphologic issues in plaque ontogeny, heterogeneity, and maturity are surveyed in Illustrations in captions I through VII :

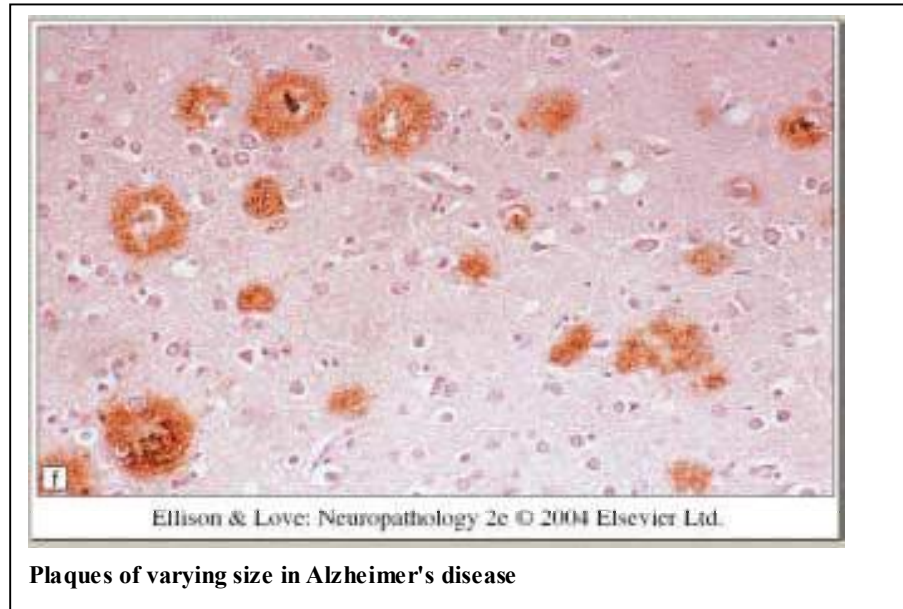
[I.] Plaque roundness, corresponds to spirochetal cyst form roundness:



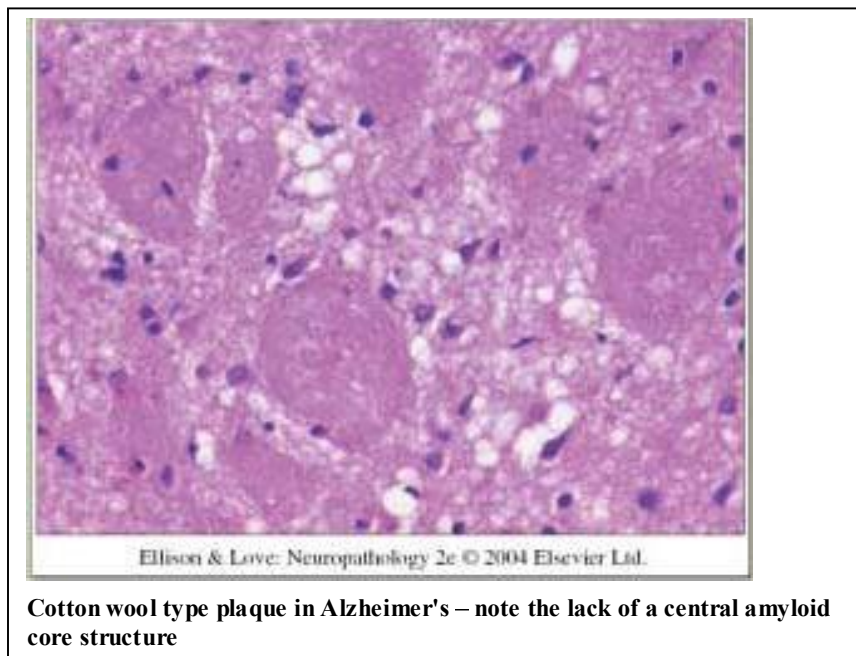
One plaque stained with silver – Alzheimer's disease – Note the round contour- and diminutive emerging plaque-like structures at 2:30 o'clock and 4 o'clock positions



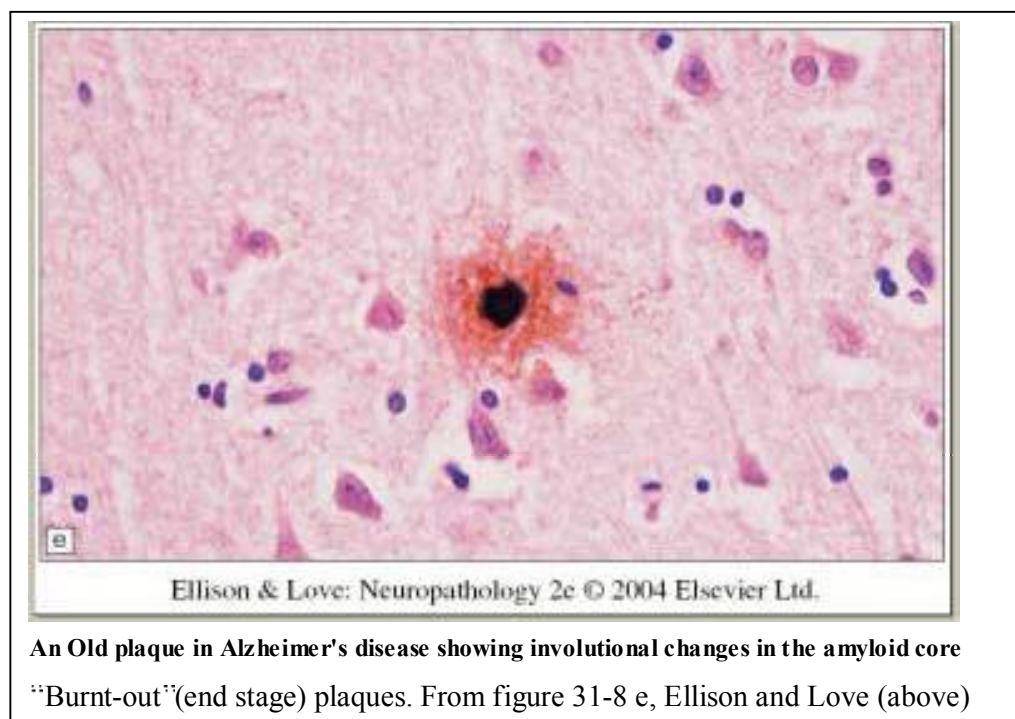
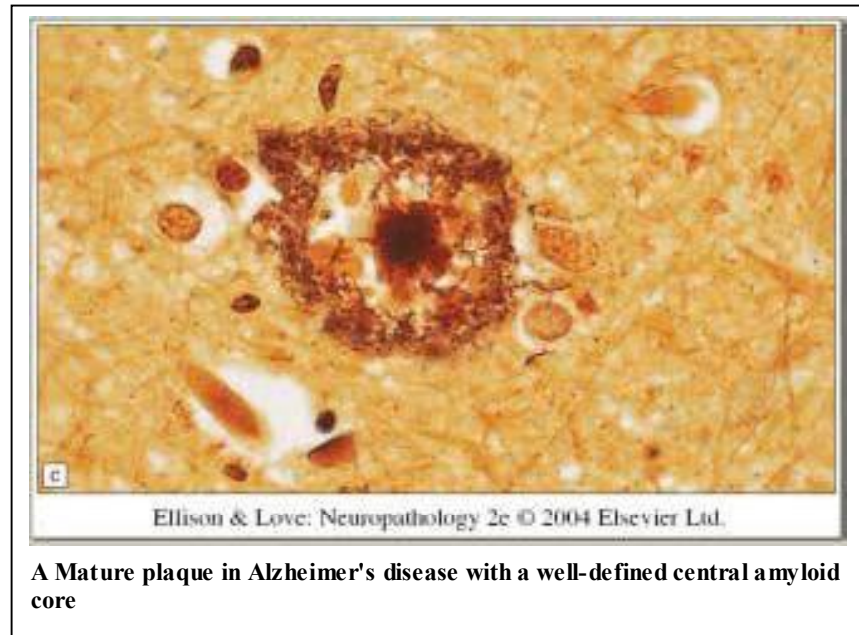
[II.] Plaque diversity in diameter (small, medium, large), corresponds to variable spirochetal cyst diameters. Small plaques lack a waxy amyloid core region.

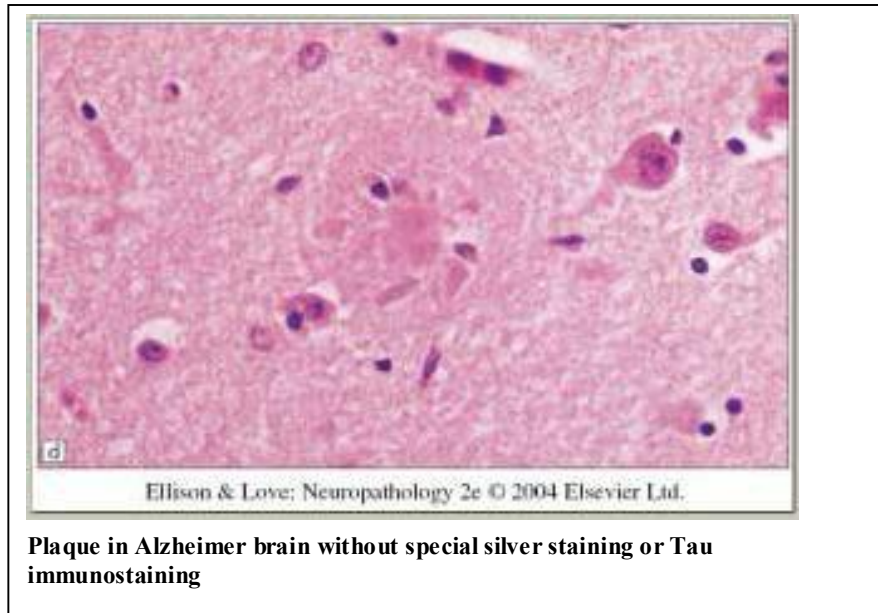


[III.] Some “cotton wool” plaques defy the congophilic amyloid core dogma for amyloid plaques. Note that all spirochetal cysts in culture conditions, are independent of a congophilic amyloid core structure.



[IV.] The phenomenon of evolution towards “histologic maturity” in plaques in AD is reminiscent of centrifugal enlargement of cystic spirochetal profiles





[V.] Low plaque density in brains of persons without dementia may be a manifestation of subclinical spirochetal infection which has not progressed as far as the cases of Alzheimer's.

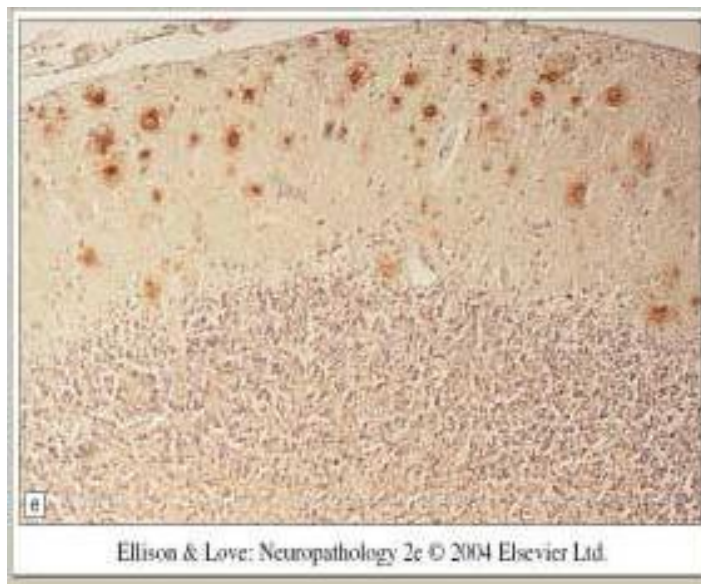
[No Image shown for incidental Plaques in autopsy brain from patients without dementia.]

Plaque densities in the CERAD system for Alzheimer grading or the Braak and Braak system for Alzheimer grading, correlate the number of plaques per unit area in the brain with degrees of dementia and stages of Alzheimer's disease.

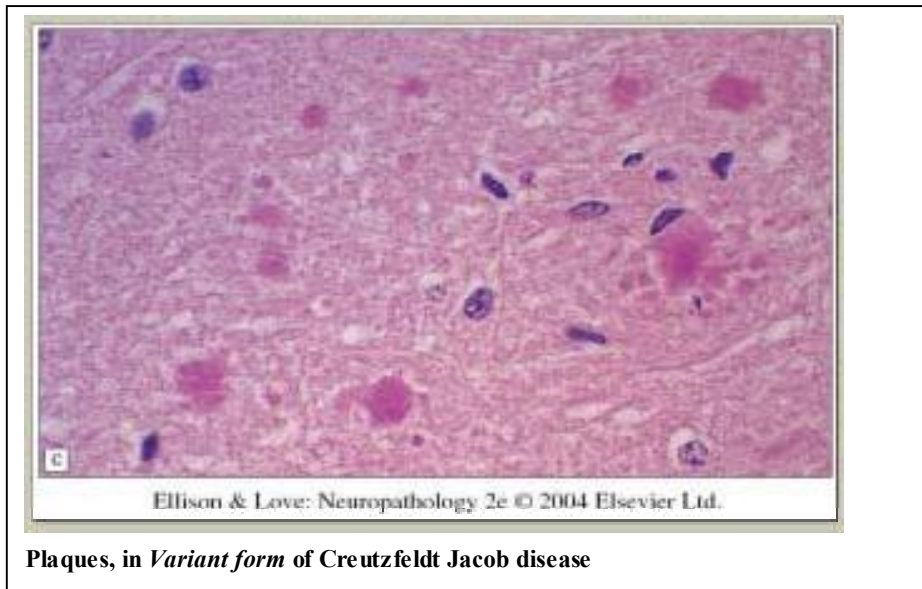
[VI] Plaques in the brains of Down's syndrome (a manifestation of spirochetal infection acquired in utero)

[No image shown for Down's syndrome Plaques].

[VII] Plaques in the brains of patients with other neurodegenerative disorders of the Non-Alzheimer type (Creutzfeldt Jacob Disease). Morphologic similarity between plaques in various Non Alzheimer's type neurodegenerative disorders, is striking.



PLAQUES, in Creutzfeldt Jacob disease of the usual type



Origin of plaques in diseases other than Alzheimer's, such as Creutzfeldt Jacob disease in which prions rather than amyloid proteins are the root cause, creates further problems for the amyloid plaque dogma. If amyloid is indeed the root cause of plaques in Alzheimer's, and prions are the root cause of Creutzfeldt Jacob disease, then what is left over to explain Creutzfeldt Jacob plaques? The common thread linking all plaques in all categories of diseased neural tissues could be the spirochete model. Diversity of clinical expressions of neuroborreliosis parallels the protean clinical expressions of *Treponema pallidum* infection in the nervous system. Tabes dorsalis and General paresis are two radically different clinical presentations of the same spirochete.

Differences of the "Neurodegenerative Phenotypes" as is shown in the Tabes to Paresis

dichotomies, might be traced to differences in spirochetal neurotropisms, based on genomic strain differences in the same spirochetal family of organisms. Variant pathogenicity in the *Borrelia* spirochetes, genetically determined, might result in diverse patterns of clinical diseases, just like the Tabes to Paresis dichotomy for *Treponema pallidum*. One spirochete produces two totally different diseases .

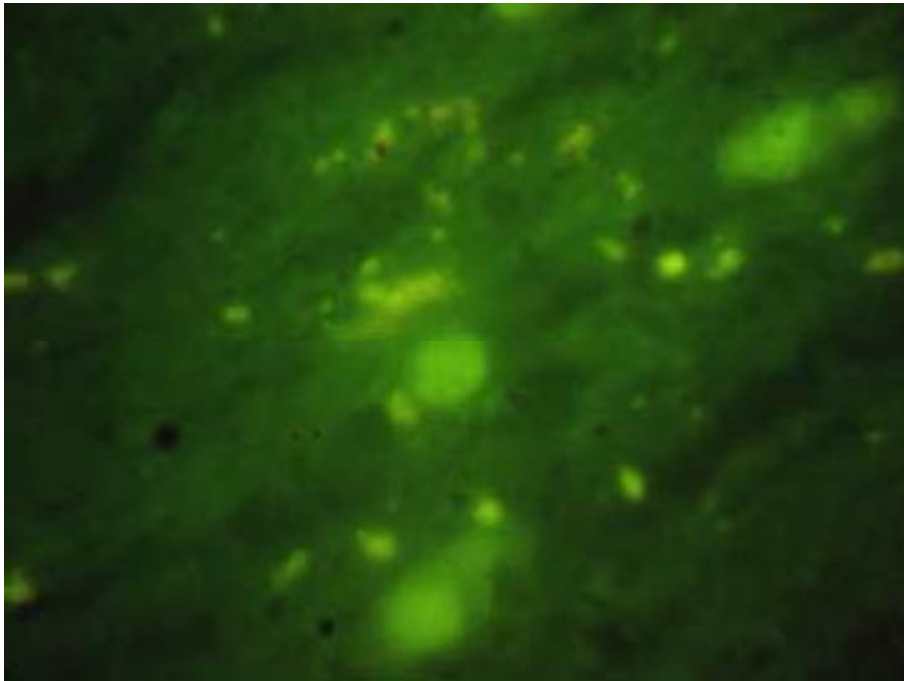
Evaluation of the Hypothesis:

Molecular interrogation of Alzheimer brain tissues has yielded evidence of specific flagellin B sequences which are recoverable from DNA digests of autopsy frozen brain tissues provided by the Harvard University McLean Hospital Brain Bank, with seven cases yielding essentially identical and heretofore unique PCR products which have been reported previously.(8.)

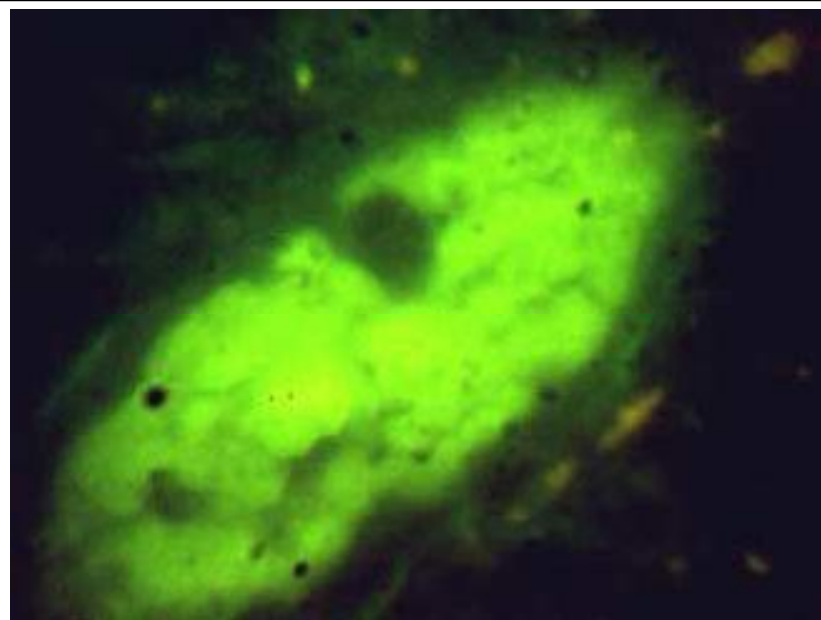
The specific DNA of *Borrelia burgdorferi* which was recovered from the Harvard Alzheimer brains was used to design DNA probes (molecular beacons). These beacons were used to interrogate the autopsy brain tissue from a single case of Alzheimer's disease, which developed 8 years after the detection of *Borrelia burgdorferi* specific antibodies in the patient's spinal fluid.

Solid phase in situ DNA hybridization was accomplished using the deparaffinized autopsy hippocampus slides with the molecular beacon for a flagellin B DNA sequence which was found in seven Harvard McLean Hospital Alzheimer Brain Bank cases.(8)

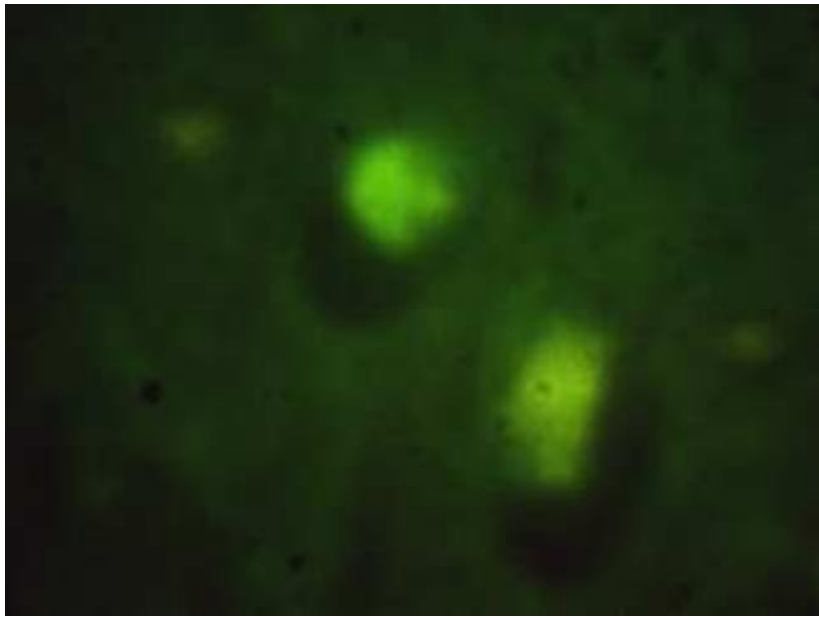
The positive domains of in situ DNA hybridization recapitulated the topographic distribution, and size, and shape of Alzheimer plaques in the hippocampus, using conventional staining methods to define plaque topography.



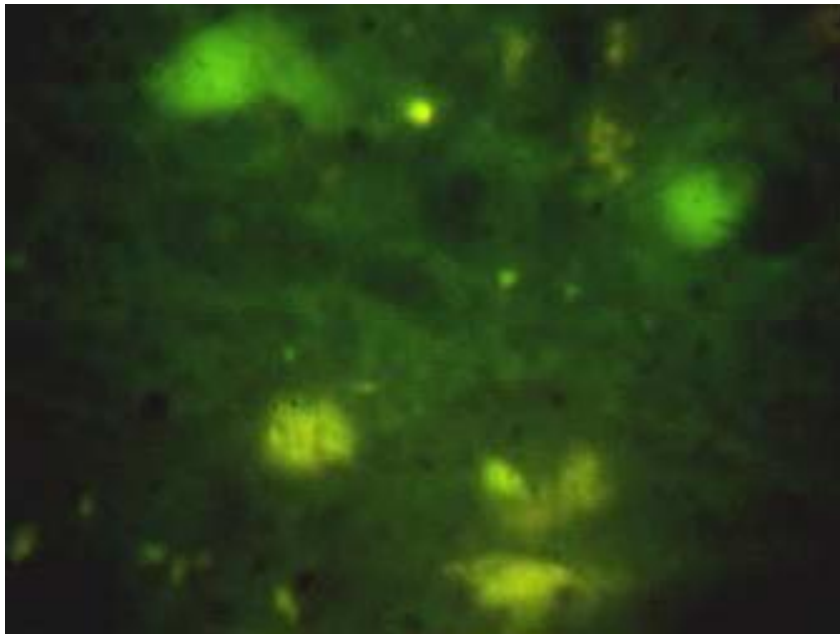
Borrelia burgdorferi flagellin DNA in situ DNA hybridization, Alzheimer hippocampus
1000x magnification.



Borrelia burgdorferi Flagellin DNA , In situ hybridization, Large Plaque
1000x original magnification



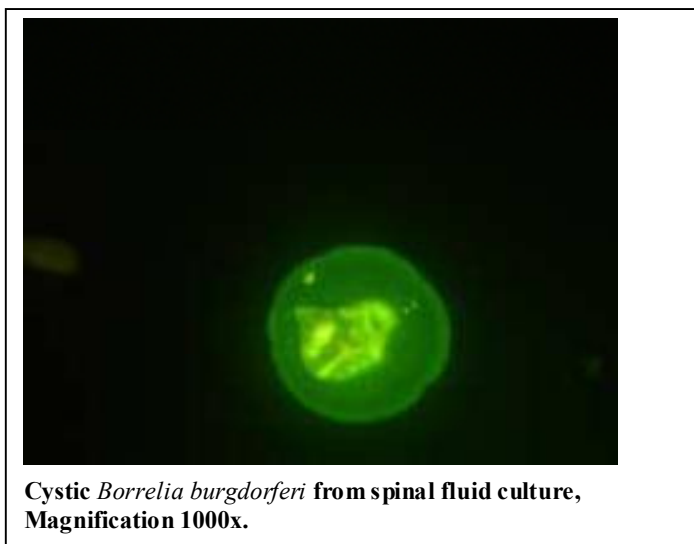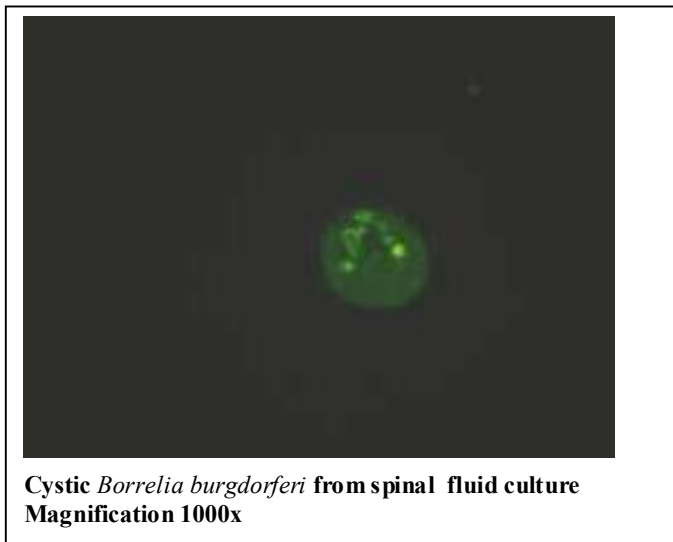
Borrelia burgdorferi Flagellin DNA , hippocampus Alzheimer's disease
1000x magnification



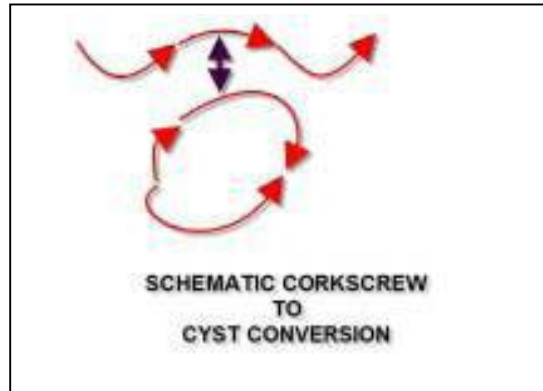
Borrelia burgdorferi flagellin DNA hybridizes to autopsy Alzheimer hippocampus ,
1000x magnification

Empiric Data:

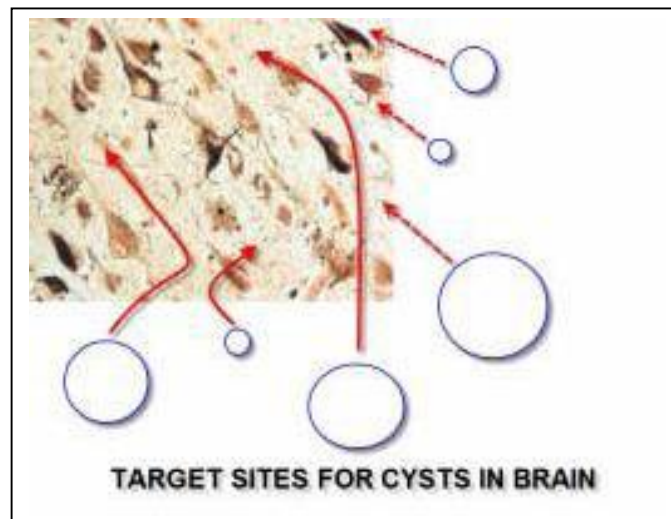
In vitro Culture of Cysts of *Borrelia burgdorferi* from the spinal fluid of another patient. (No dementia) Spinal fluid negative for spirochetes by darkfield at commencement of culture, with cysts detected at 16 months later. Spinal fluid antibodies positive in ImmunoBlot at a regional reference laboratory.

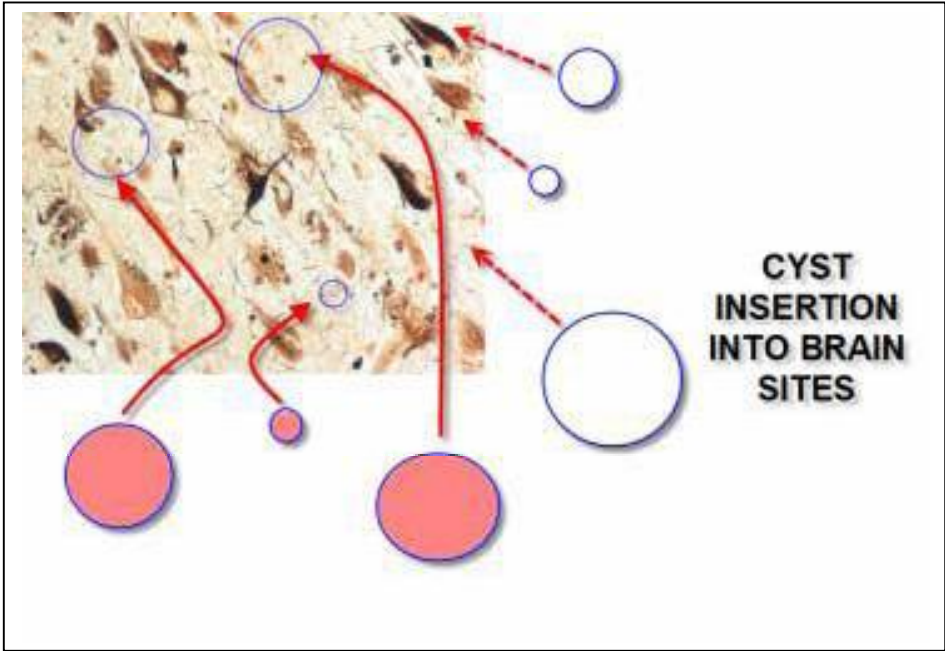


Line drawings of the interconversions of corkscrew shaped *Borrelia burgdorferi* into Cystic spirochetes .

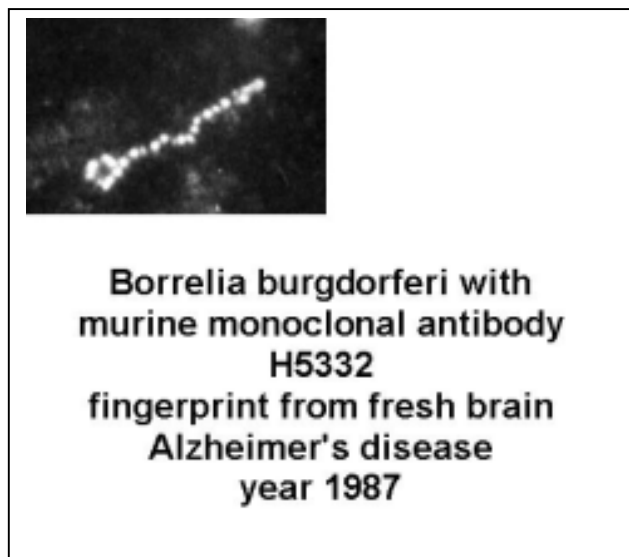
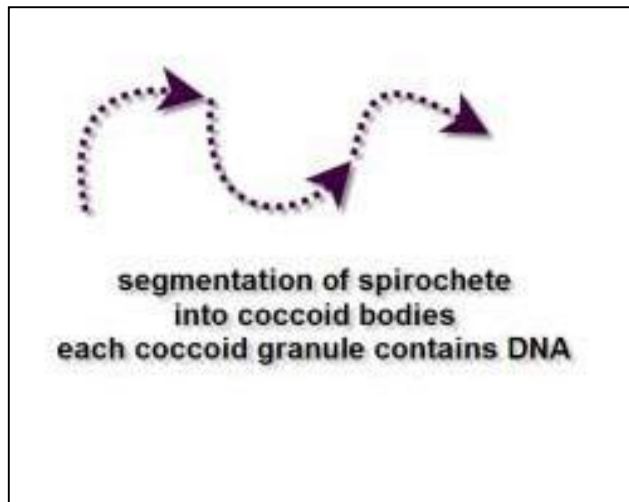


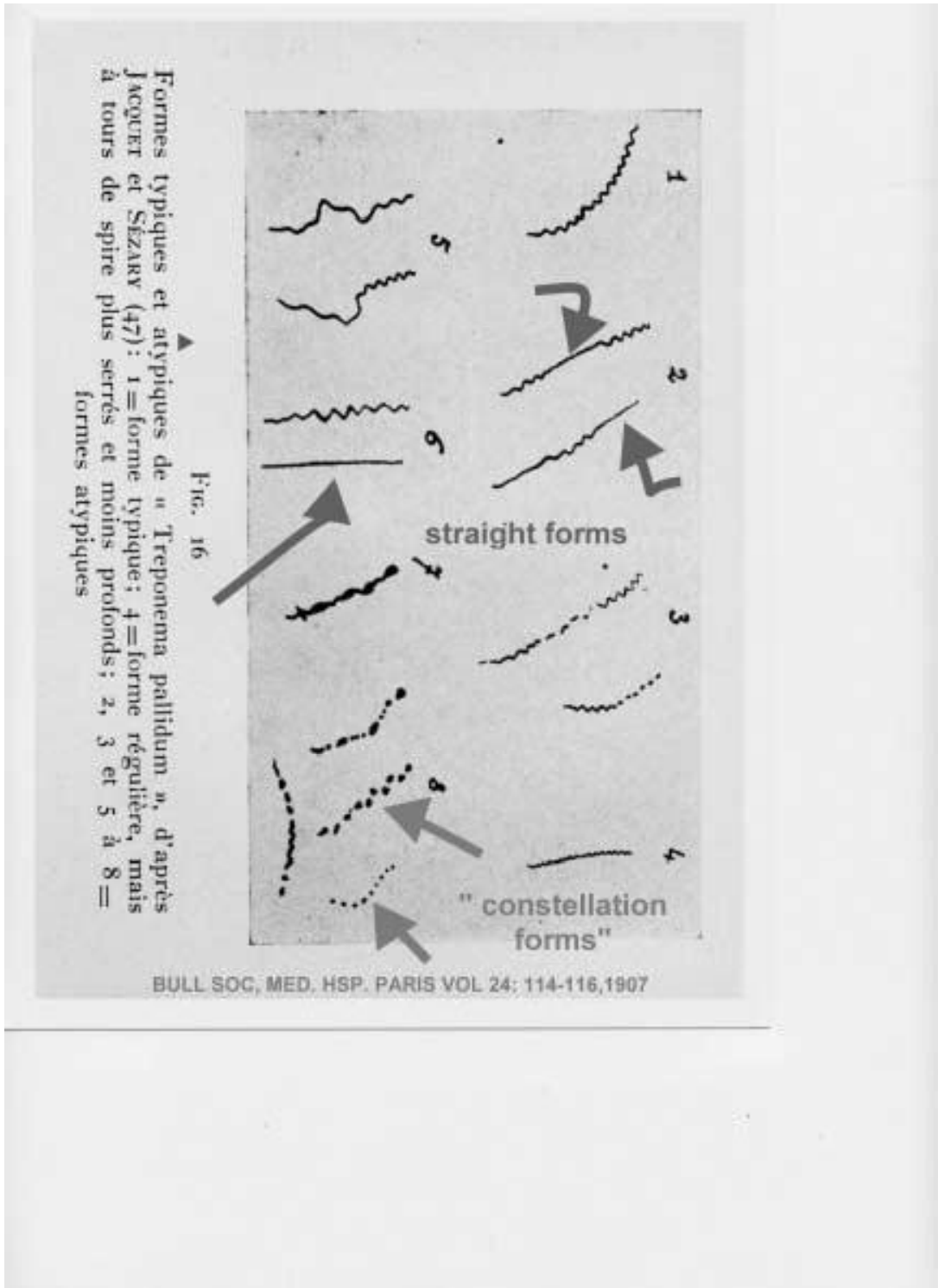
INSERTION of Cysts Cartoon





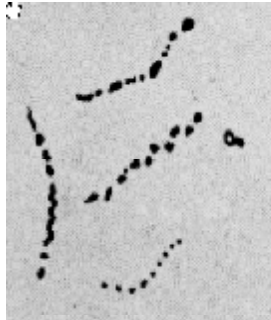
Line drawings of the interconversion of corkscrew shaped *Borrelia burgdorferi* into coccoid "dot-like" spirochetal "packets" of DNA, (also called granular spirochetes, which might explain all cases of granulovacuolar degeneration of hippocampal neurons in Alzheimer's disease.



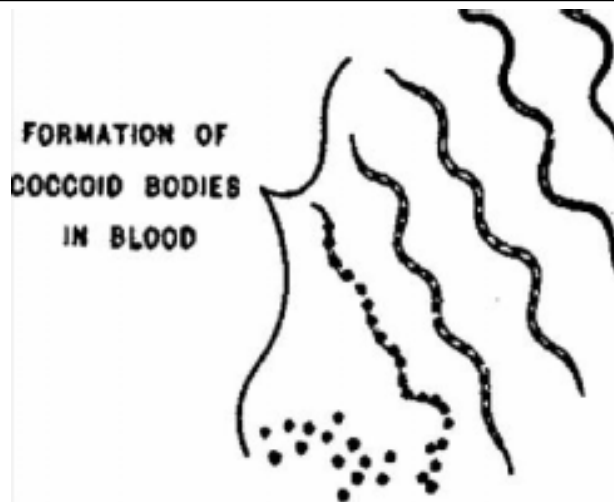


Formes typiques et atypiques de « *Treponema pallidum* », d'après JACOET et SÉZARY (47): 1 = forme typique; 4 = forme régulière, mais à tours de spire plus serrés et moins profonds; 2, 3 et 5 à 8 = formes atypiques

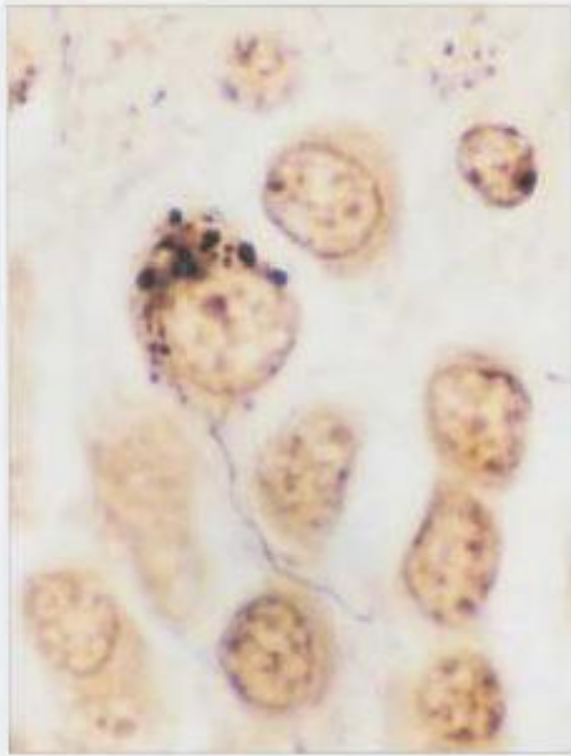
Montage of variant spirochetal profiles from syphilis
Year 1907



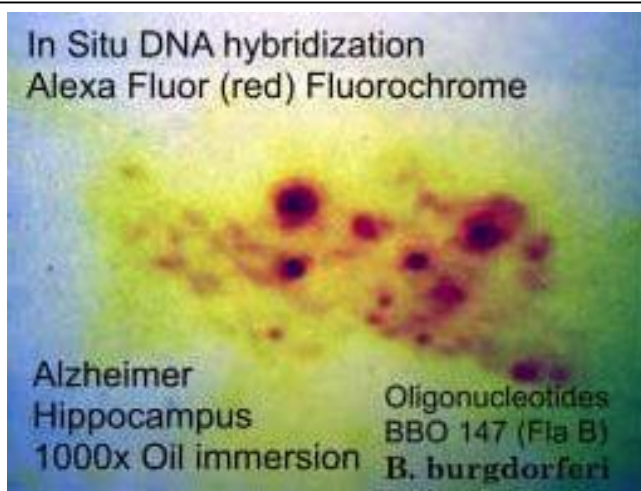
Year 1907, Paris France
Jacquet and Sezary
line drawings of syphilis
granular "constellation" forms
of *Treponema pallidum*



Hindle, 1912, emergence of granular "coccoid" forms from spirochetes



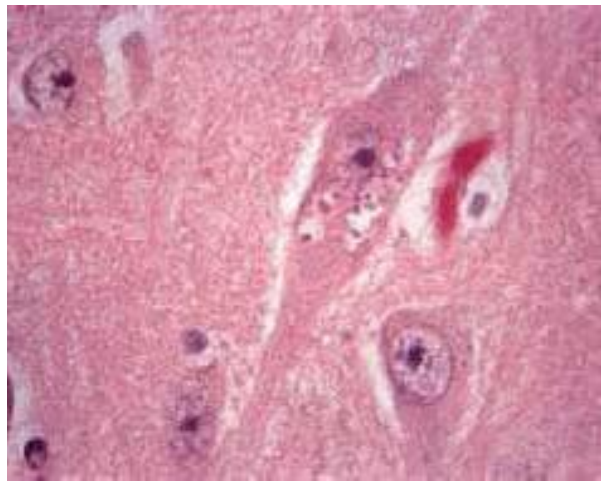
Granular bodies within hippocampal nerve Alzheimer's disease at 9 o'clock to 2 o'clock positions with spirochete – like profile at 6 o'clock, Bielschowsky stain , original slide borrowed from theHarvard McLean Brain Bank . This case was used in Reference 8 (Polymerase Chain Reaction – Molecular Interogation for Flagellin B DNA study), Magnification 1000x,



In situ DNA hybridization with flagellin DNA probes from *Borrelia burgdorferi*. Alzheimer hippocampus. Red signals within the cytoplasm of a nerve cell recapitulate the cytoplasmic profiles of granulovacuolar degeneration in Alzheimer's disease.

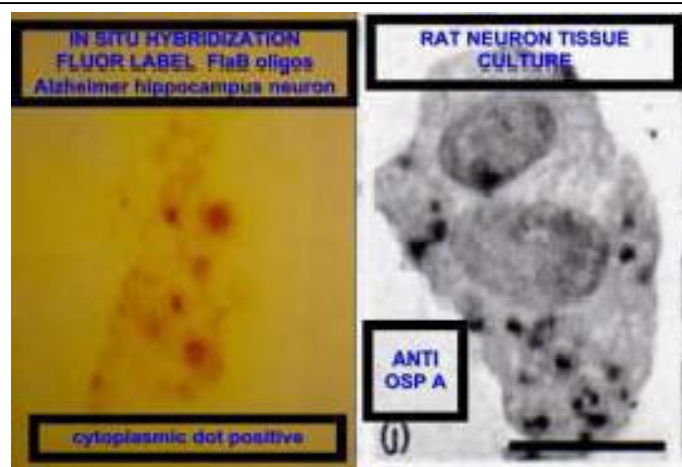


In situ DNA hybridization hippocampus tissue section from Alzheimer's disease showing dot like positive signals within the cytoplasm of nerve cells using flagellin DNA probe for open reading frame BBO 0147 of *Borrelia burgdorferi*, 1000x magnification



Granulovacuolar degeneration in neuron Alzheimer's disease

From Ellison and Love, Neuropathology, Copyright Elsevier pub. all rights reserved.



Reference 9.

Comparison of intracellular *Borrelia* spirochetal profiles

Right panel shows rounded coccoid bodies within the cytoplasm of a rat nerve cell incubated in tissue culture with virulent *Borrelia burgdorferi* for several weeks to yield evidence of intracellular penetration of spirochete fragments (reactive with monoclonal antibody H5332, which uniquely recognizes an epitope of outer surface protein A (OspA) which defines *Borrelia burgdorferi* at the proteomic level. (Miklossy et al)
 Left panel is a human Alzheimer nerve cell which shows positive signals in the cytoplasm in a granulovacuolar degeneration profile. (In situ DNA hybridization with flagellin B DNA of *Borrelia burgdorferi*.)

Consequences of the Hypothesis:

The hypothetical proof that **ALL** of the plaques in the brains of patients with Alzheimer's disease are positive for the DNA of *Borrelia burgdorferi* would silence the argument, now currently discussed by some neuropathologists which is as follows:..

“ . . coincidence links those cases of Alzheimer's disease showing detection of antibodies in blood testing against *Borrelia burgdorferi* . . .” This argument is wrapped in the caveats that Alzheimer's is a relatively common disease. Lyme borreliosis is a common disease. Overlap of the two conditions is expected by chance alone.

Refutation of the “pure coincidence” gambit is found in the localization of the DNA of the alleged pathogen to the sites of tissue injury which are definitional for Alzheimer's. DNA of the alleged perpetrator at the scene of the crime constitutes “molecular proof” of a spirochetal (*Borrelia burgdorferi*) pathogenesis. I offer these ideas as a gift to anyone who might find some logic in them; the fruit of 20 years of labor by one man working to find the cause of the disease which took the life of his grandfather, with the hope that Alzheimer's disease might follow the eventual pathway to antispirochetal therapy , which was blazed by a hero, Dr. Hideyo Noguchi ,in the year 1913, when he proved the spirochetal pathogenesis of General Paresis of the Insane.

Acknowledgments:

This work was supported by a research grant from the Turn the Corner Foundation, New York, New York and ILADS (International Lyme Disease and Related Disorders Society), and generous institutional support from the St. Catherine of Siena Medical Center, Smithtown, New York.

The Harvard University McLean Hospital Brain Bank provided frozen Alzheimer's disease brain tissues for the molecular interrogation studies by polymerase chain reaction with flagellin B primer oligonucleotides.

Sequencing of PCR products was completed at Lark Technologies, a division of Genaisance Inc.

Molecular beacons were designed by Alan B. MacDonald, MD, and synthesized by Gene Link Inc, Hawthorne, New York.

Judith Miklossy MD offered expert critiques for improving the experimental designs for the granulovacuolar degeneration module in this work. Dr. Miklossy's work in *Borreliosis* and Alzheimer's disease has been a source of inspiration and a model of academic excellence.

References:

1. MacDonald, A. B., "Concurrent Neocortical *Borreliosis* and Alzheimer's Disease- Demonstration of a Spirochetal Cyst Form", *Annals of the New York Academy of Sciences*, 1988, 539:468-70.
2. Rubel, Joanne, "Spirochetal Cysts, L-forms, and Blebs, Observations from 1905 to 2005, Web access, <http://www.lymeinfo.net/medical/LDBibliography.pdf>, date visited February 17,2006.
3. MacDonald, A.B., "*Borrelia* in the brains of patients dying with dementia", *Journal of the American Medical Association*, 1986, 256:2195-6.
4. MacDonald, A.B., Miranda, J.M., : "Concurrent Neocortical *Borreliosis* and Alzheimer's Disease", 1987, 18:: 759-61.
5. Miklossy, J., "Alzheimer's Disease- a spirochetosis?", *Neuroreport*, 1993, 4:841-848.
6. Miklossy, J.,Khalili, K., Gern, L, et al, "*Borrelia burgdorferi* persists in the brain in chronic neuroborreliosis and may be associated with Alzheimer disease", *J. Alzheimer's disease*, 2004, 6: 639-649.
7. MacDonald, A. B., "Cystic *borrelia* in Alzheimer's disease and in Non-Dementia Neuroborreliosis", 10th International Conference on Alzheimer's disease and Related Disorders [ICAD] , Abstract 06-A-2798-Alz, 2006.
8. MacDonald, A.B., "Transfection "Junk" DNA – A link to the pathogenesis of Alzheimer's disease?", *Medical Hypothesis*, 2006 Feb 13th (Epub ahead of print).

9. Miklossy, J., Kris, A., Radenovic, A., et al, "Beta Amyloid deposition and Alzheimer's type changes induced by *Borrelia Spirochetes*", *Neurobiology Aging*, 2006, 2:228-36.

Spirochete Life Cycle?
page 1

A Life Cycle for *Borrelia* spirochetes?

Alan B. MacDonald, MD

St Catherine of Siena Medical Center

Department of Pathology

50 Rte 25 A

Smithtown, New York, USA 11787

Correspondence to:

Alan B. MacDonald, M.D.

1 Franciscan Lane, Smithtown, New York, 11787

Telephone 631-862-3764 (voice), 631-862-3863 (Fax)

email: inmacdonald@yahoo.com

Supported by the Turn the Corner Foundation

New York, N.Y.

Spirochete Life Cycle?
page 1

A Life Cycle for *Borrelia* spirochetes?

Alan B. MacDonald, MD

St Catherine of Siena Medical Center

Department of Pathology

50 Rte 25 A

Smithtown, New York, USA 11787

Correspondence to:

Alan B. MacDonald, M.D.

1 Franciscan Lane, Smithtown, New York, 11787

Telephone 631-862-3764 (voice), 631-862-3863 (Fax)

email: inmacdonald@yahoo.com

Supported by the Turn the Corner Foundation

New York, N.Y.

Abstract:

Subsequent to Schaudinn and Hoffman's visualization of *Treponema pallidum* in 1905, many distinguished syphilologists proposed that spirochetes have a life cycle. What is the "essence" of a life cycle? Simply put, life cycles are diverse arrays of life forms, which emerge in an ordered sequence; which are "connected" to one another across primary and secondary hosts, and constitute a cycle with "circular" relationship between hosts. Fecal oral life cycles and blood-to-blood life cycles are exemplary of host parasite relationships in this realm. The "blood to blood" begins and ends with an insect taking a blood "meal". In this operative scenario, a "blood -less" insect functions simultaneously as a hypodermic needle and as an incubator for some of the infectious components. The initial phase is inside the body fluid compartment of an insect. The second phase is in the blood or body fluid of a warm-blooded mammal. Third, is the phase inside the cell of a mammalian host. And a final portion of the "life" marked by "death" of the parasitized mammalian cells and the release of infectious parasites which return to the "warm" blood where the "cold blooded" vector again takes a blood meal. The cycle then begins again. In each phase of a blood to blood life cycle, the infectious agent changes its shape. Blood phase "profiles" look different from "tissue phase" profiles. Some of the tissue phase profiles may be "invisible". *Borrelia* spirochetes offer an excellent example of a life cycle, by virtue of the insect vector to mammalian "piece", the blood and intracellular residence "pieces" and the morphologic diversity "piece". Stereotypes of what a spirochete "should" look like, have actually produced a state of "perseveration" in spirochetal pathobiology. We have been "stuck" like a broken record,

Spirochete Life Cycle?

page 3

on the corkscrew form, and have failed to see the rest of the life cycle. Cystic, granular, and cell wall deficient spirochetal profiles, which were well known in the 19th and 20th centuries by such titans as Schaudinn, Hoffman, Noguchi, Delamater, Steiner, and Mattman, have been repudiated by professional microbiologists, and by pathologists who practice and who confer the status of 21st century truths in microbiology matters. Proper microscopic study, as is required by Dr. Robert Koch's second postulate, for establishing links between microbes and disease, presupposes that the microscopist be aware of the complete array of morphologic repertoires of the alleged pathogen. (Morphologies, which are herein introduced)

(Word count in Abstract = 399 words)

Introduction:

In the discussions of life cycles, diversities of shapes and sizes of parasites are not optional constructs. Entered as evidence "Exhibits A, B, C.." herein are images of the morphologic diversities of *Borrelia* spirochetes. Corkscrew shapes are "Exhibit A". These are concentric coaxial cylinders with axial internal periplasmic flagellae in the outermost compartment. Plasticity of forms for Exhibits B., C.) begins with the outer surface membrane of the *Borrelia* spirochete. Protrusions from the outer membrane may be small caliber "blebs". Blebs from *Borrelia* are capable of "embolic" behavior. Cystic forms are a larger caliber variation on theme of rounded outer membrane invested derivatives from *Borrelia* spirochetes. Several Cystic varieties exist. The first of these is the "inducible" cystic *Borrelia*, which is easily produced by placing the corkscrew forms into a "hostile environment" such as liquid media containing antibiotics, or acid pH, or starvation conditions. Under these circumstances, the corkscrews "round up" and are internalized. This "encystment" is a rapid event. The shortest elapsed time in video microscopy for encystment to begin is less than one minute, but longer encystments have been noted experimentally. Like a marsupial in a pouch, the corkscrew is "infolded" into its own surface membrane. Darkfield microscopy and electron microscopy studies demonstrate within this variety of cystic *Borrelia*, that the "parent" form is still visible, and that the corkscrew form is capable of rapidly re-emerging from its "cocoon" if the adverse external environment is corrected. The simple concept of the retractable carpenter's clip-on metal tape ruler facilitates the comprehension of this "early" cystic profile. Alternatively, another cystic profile may consist of an empty membrane bound

Spirochete Life Cycle?

page 5

“bag of fluid”. Varieties of the “bag of fluid” cyst may exist as either cyst forms of the “empty type” or cysts which are almost empty with little discernable internal filamentous or nucleoid-like central luminal content. And finally, there is the “Aged” cyst form of *Borrelia*, which contains dense “nucleoid-like” granules within the cyst. Aged cysts are incapable of rapid reversion to motile corkscrew forms. Ruptured Aged *Borrelia* cysts discharge a shower of granules into the environment. Granular discharge via rupture recalls other “attack” mechanisms of *Chlamydia* and *Toxoplasmosis*. *Treponemal* spirochetal cysts described by Dr Edward Delamater, show virtually identical structure with the *Borrelia* cysts; namely small, medium, and large profiles, granule and spirochetal content, and origin from the outer surface membrane.

A second sphere in the *Borrelia* life cycle is the granule. Granular spirochetal forms were known to Noguchi and his contemporaries. Granular derivatives emerge from “senescent” spirochetes, by a process of “segmentation” of the inner DNA containing regions of the axial cylinder. The granular elements contain either DNA or RNA, derived from the “parent” and incrementally evolve from a “Morse Code” dot and dash profile within the cylinder. When released from the confines of the inner intact spirochetal cylinder, these granules are able to “round up” in liquid media. Some released granules have a small radius and others a larger radius. Jacquet and Sezary in their studies of *Treponema pallidum* in Chancre fluid under darkfield illumination described granules such as these. Small radius granular forms are denovo round forms, whereas large radius granular forms appear to begin as sausage shaped segments when they are confined inside the spirochetal cylinder. Rounding occurs when the sausages are released from the “corset” of the inner cylinder upon dissolution of the corkscrew form. It is not unusual to

Spirochete Life Cycle?

page 6

see small radius and larger radius granular forms in the same microscopic fielding tissue or in chancre darkfield preparations. Dr Gabriel Steiner correctly implicated granular spirochetal profiles as agents of tissue injury in his landmark studies of human autopsy tissues from Multiple Sclerosis. In Alzheimer's disease the granules within diseased and dying nerve cells of the hippocampus may be internalized *Borrelia* spirochetal granular forms, based on DNA in situ hybridization data.

The third sphere consists of L forms of spirochetes. L forms describe any bacterium which has lost its cell wall, but which has not lost its bacterial viability in the process. Spirochetal L forms are just as reasonable and equally contentious as cell wall deficient forms of any other microbe. If the Lister Institute conceptual model is embraced, then morphologic plasticity of *Borrelia* L forms is not a political "hot button". Cell wall deficient microbes share with the "snowflake" the constraints that are implicit with any "soap bubble", namely an ephemeral existence. Horizontal DNA transfer from *Borrelia* to other prokaryote or to eukaryotic cells might be mediated by L forms.

Additional special types of spirochetal morphology are addressed in the last 2 "bullets", namely liberated periplasmic flagellae (undocked from their parent corkscrew forms) and finally, genetic origins of spirochetes which do not demonstrate the corkscrew profile.

Naked or "sheathed" periplasmic flagellae, isolated from the parent intact corkscrew shaped borreliae offer yet another morphologic variation on the theme of borrelia spirochetal morphologic diversity. These forms are rigid, non motile, very small in caliber and very regular in the pattern of their coiling.

Finally, various mutations of the flagellin genes of *Borrelia*, have provided

Spirochete Life Cycle?

page 7

a “molecular rationale” for the “straightened spirochetes” which were illustrated in papers from the 19th and 20th centuries. Spiral morphology is, in some but not in all cases, “tethered” to the periplasmic flagellae. In the simplest case, no flagellae (due to a mutation in the flagellin complex of genes, translates into a Nonmotile spirochete which looks like a bacillus form; that is straight, rigid, and in the current vernacular..., “totally NOT a Spirochete” (sic). Electron microscopic studies of Flagellin-less spirochetal mutants prove that these bacillary non motile forms are indeed spirochetal. Such straightened spirochetal forms were tabulated by Jacquet and Sezary in the year 1907. A different set of “molecular rules” for mutant forms of treponemes of the oral cavity, shows the converse case. Some oral *Treponemal* mutant forms which are “flagellin-less” become more regularly coiled and more perfect corkscrews, when compared with their species cohorts who have an intact flagellin gene expression, and demonstrate Non coiled Axial “Bulbosities” which are in all respects identical to the Atypical *Treponema pallidum* organisms which Warthin and Olsen depicted in 1930 in their Matrix montage of morphologic variations of syphilis in autopsy cases of Syphilitic Aortitis.

A tolerance for spirochetal morphologic “plasticity” is indeed prudent. An awareness of a spirochetal life cycle is an intellectual asset. Repudiation of the spirochetal life cycle nosology is a medical and scientific liability. In a court of law, it might be said “ignorance of a life cycle for spirochetes is no excuse”. We must get it right for the sake of the patient.

Evaluation of the Hypothesis:

Peer reviewed scientific reports from the published literature dating back to 1900 must be scrutinized for images of *Borrelia* and *Treponema* which might “populate” the scaffolds of a tripartite life cycle consisting of intersecting but autonomous “rings” of replicating, DNA containing spirochetal forms of the following types: granules (a la Hindle’s infective Granule life cycle), cysts (a la Delamater’s myriad cystic profiles for *Treponema* species), corkscrews and their Cell wall deficient progeny. An image database must be compiled and collated. Pure laboratory cultures of *Borrelia burgdorferi* shall be evaluated in vitro and in vivo after various incubations ranging from one day to beyond one year to accommodate slow to replicate individual components. Spirochetal morphology should be photographed in preparations stained with 19th and 20th century methods, such as silver stains (Warthin Starry and Krajian methods), and 21st century technologies to demonstrate DNA (Acridine orange, Picogreen (Invitrogen Inc) (a reagent for double strand DNA staining), Oligreen (Invitrogen Inc) (a reagent for single strand DNA staining)) and specific *Borrelia* specific DNA markers such as Molecular beacons which are optimized to find only *Borrelia* specific DNA sequences in laboratory models. Darkfield microscopy, and Phase contrast microscopy illumination shall be used to identify cell wall deficient L forms.

Empirical Data:

Cystic *Borrelia* forms (At least three categories are proposed)

1. "Primary" type cysts – Rapidly reversible to motile corkscrew shaped forms:

Cystic *Borrelia* rapidly emerge from the motile corkscrew shaped forms as a response to "stressful conditions" in their environment.

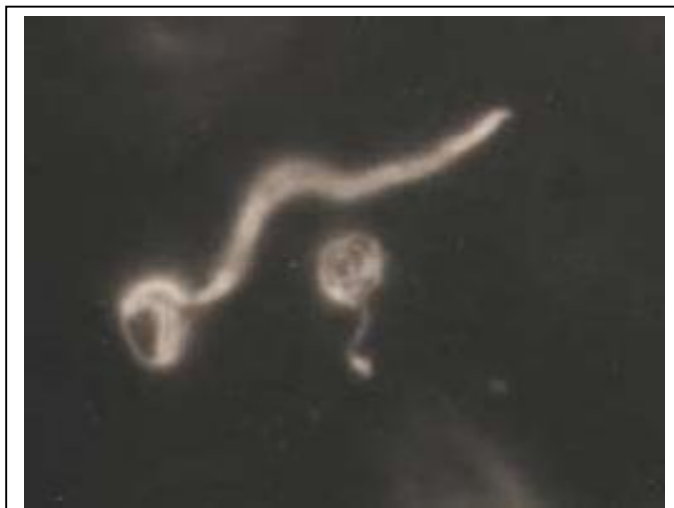

Figure 1 Cystic Forms of *Borrelia burgdorferi* (American Type Culture Collection 35210), darkfield image 1000x, original, Alan MacDonald, MD unpublished, Photograph date 1988

1. "Primary" type cysts (continued)

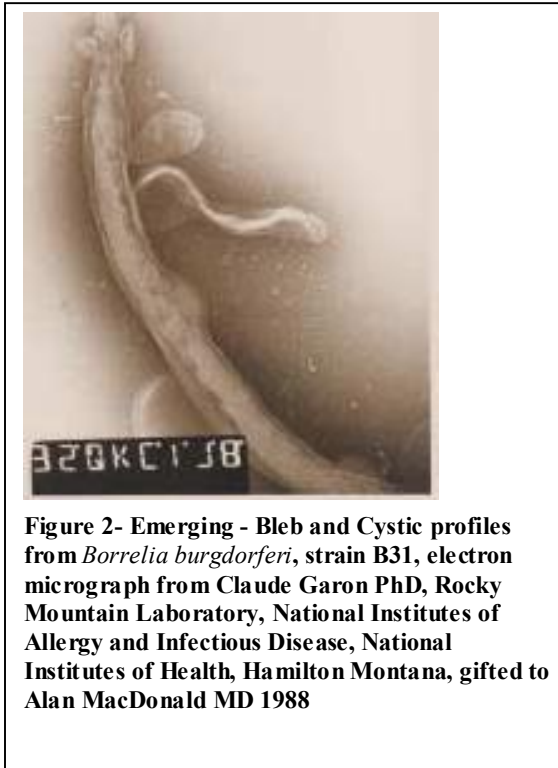


Figure 2- Emerging - Bleb and Cystic profiles from *Borrelia burgdorferi*, strain B31, electron micrograph from Claude Garon PhD, Rocky Mountain Laboratory, National Institutes of Allergy and Infectious Disease, National Institutes of Health, Hamilton Montana, gifted to Alan MacDonald MD 1988

2. "Secondary" type Cysts of *Borrelia* – No residual internal corkscrew remnants are seen. ("Empty" type cysts or nearly empty cyst content" but uniformly positive for single strand type spirochetal DNA)

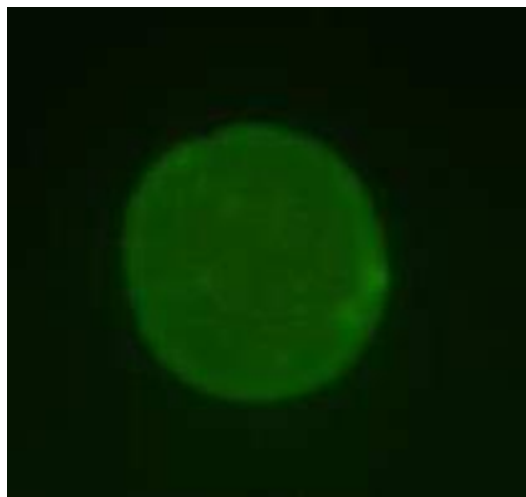

Figure 3 Cystic *Borrelia burgdorferi* from cultured human spinal fluid, 1000x original magnification, Oligreen stain for single strand DNA, Western Blot positive for antibodies to *Borrelia burgdorferi* in spinal fluid. Oligreen stained preparation (demonstrates single strand DNA – green signal – within the otherwise "empty cyst". 1000x magnification, Alan MacDonald ,MD 2006.

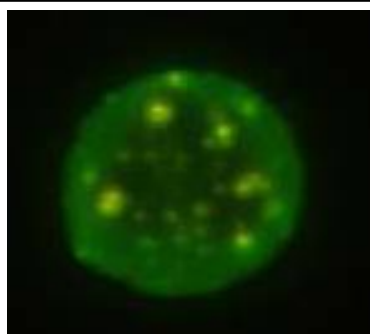
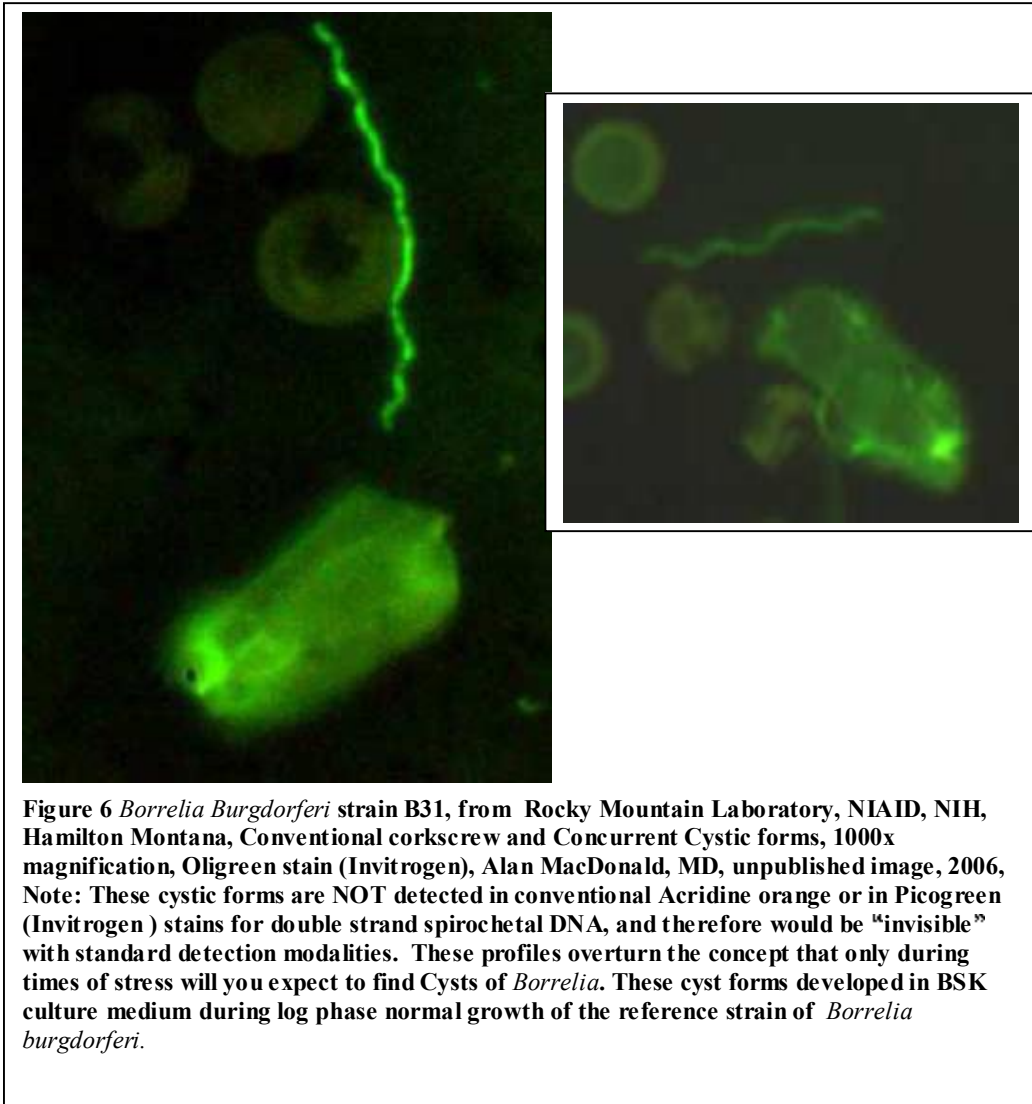


Figure 4 Cystic *Borrelia burgdorferi* from spinal fluid culture for comparison, showing internal DNA granular foci, 1000x magnification, Oligreen stain for single strand DNA

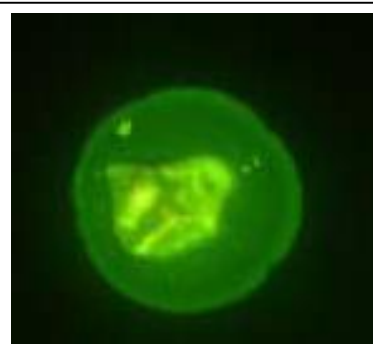

Figure 5 Cystic *Borrelia burgdorferi* from spinal fluid culture, for comparison, showing a dense "nucleoid-like profile", 1000x magnification, Oligreen stain for single strand DNA.

3. Tertiary ("Chronic" or "Latency" type) *Borrelia* cystic forms containing internal granular structures of variable caliber.



Granular and so called "Morse code" forms of *Borrelia* which are derived from corkscrew shaped spirochetes:

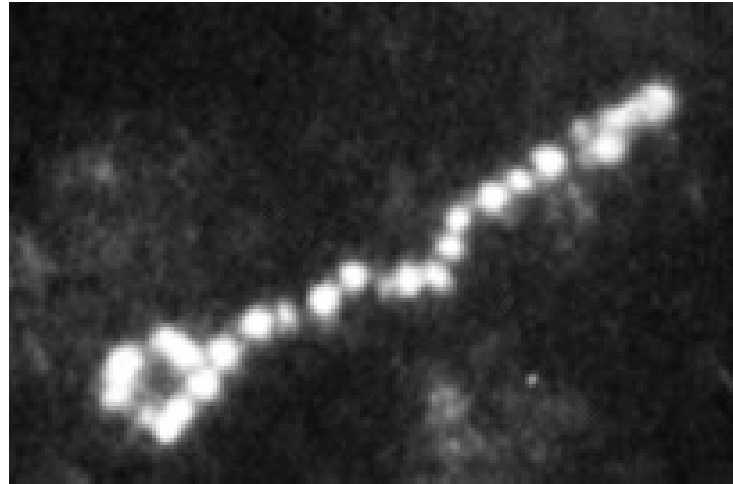


Figure 7 *Borrelia burgdorferi* in transition to granular form, Murine Monoclonal antibody H5332 (Outer surface protein A), Indirect Immunofluorescence, 1000x magnification, Alan MacDonald, MD, (note variable caliber for the individual granular elements, in a "Morse code – dot and dash array", 1000x magnification.



Figure 8 *Borrelia burgdorferi*, ATCC 35210, Warthin Starry silver stain, 1000x magnification, from culture aged one year. Note the evolving segmentation of granular forms inside the cylinder and the evolving cystic profile at the apex.

Spirochete Life Cycle?

page 14

Cell wall deficient forms of *Borrelia* – devoid of a cell wall –detectable only in hypersonic liquid media under dark field illumination using maximal and optimized optical resolutions:

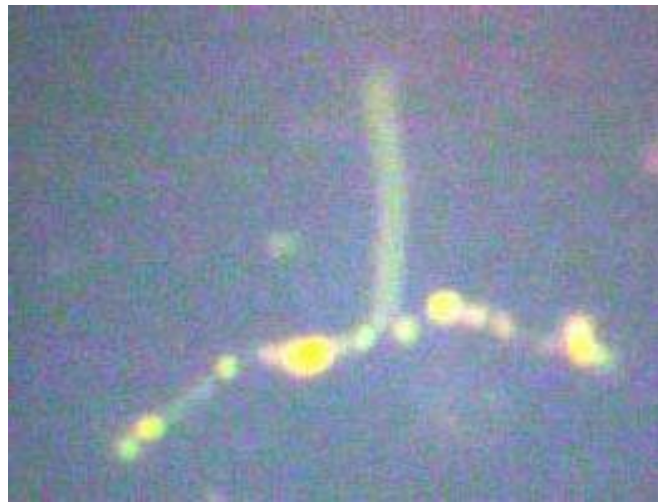

Figure 9 Cell wall deficient "L form" emerging from *Borrelia burgdorferi* ATCC 35210 (strain B31) culture after one year, Alan MacDonald, MD, unpublished image , darkfield 1000x with oil immersion objective outfitted with a correction collar. Note the beaded granular parent spirochete attached to the L form.

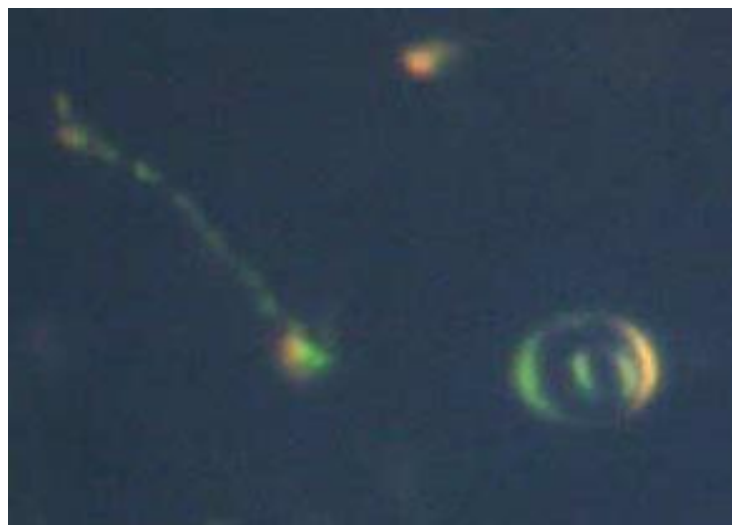


Figure 10 L form of *Borrelia burgdorferi* strain B31 in 1-year-old culture, 1000x magnification darkfield, L form represented at 3 o'clock position by a circular profile within a circular "soap bubble", conventional corkscrew form at 9 o'clock position.

Detached Periplasmic Flagellae of *Borrelia* and precursor "Extruded" periplasmic flagellae still attached to parental corkscrew shaped forms.

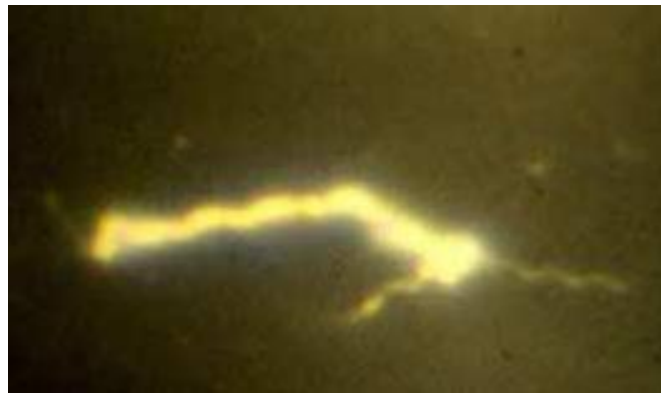
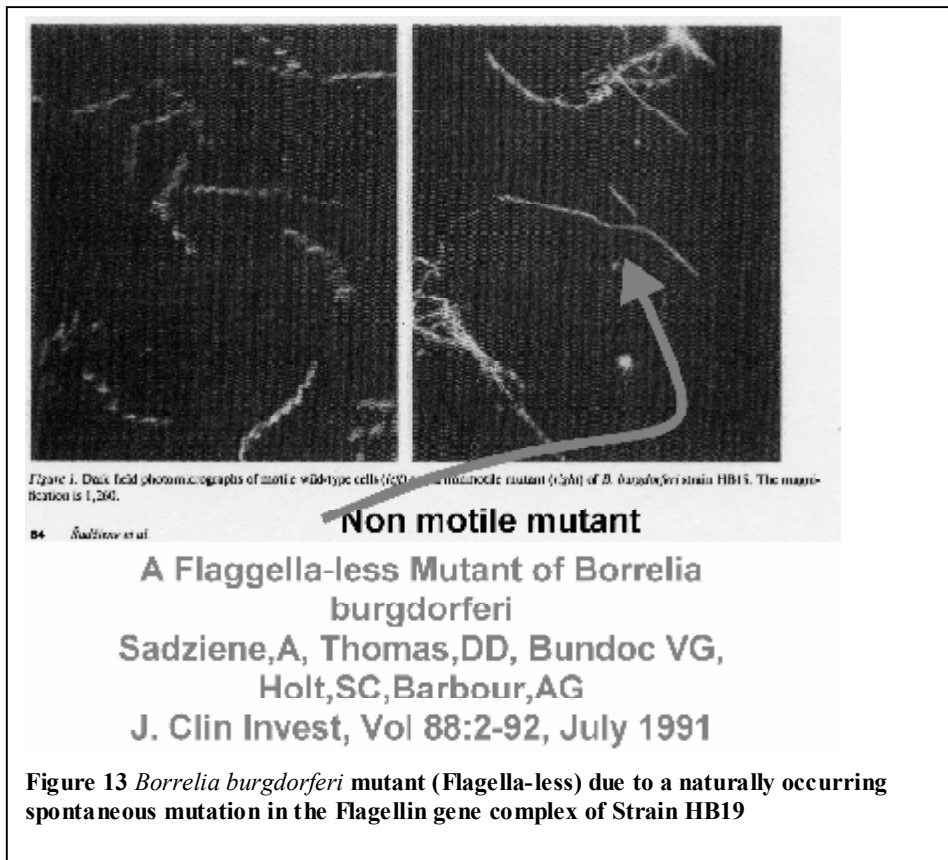


Figure 11 Extruded periplasmic flagellae of *Borrelia burgdorferi*, at 3 o'clock, 7 o'clock and 10 o'clock, 1000x darkfield, Alan B. MacDonald, MD (unpublished image 1988)



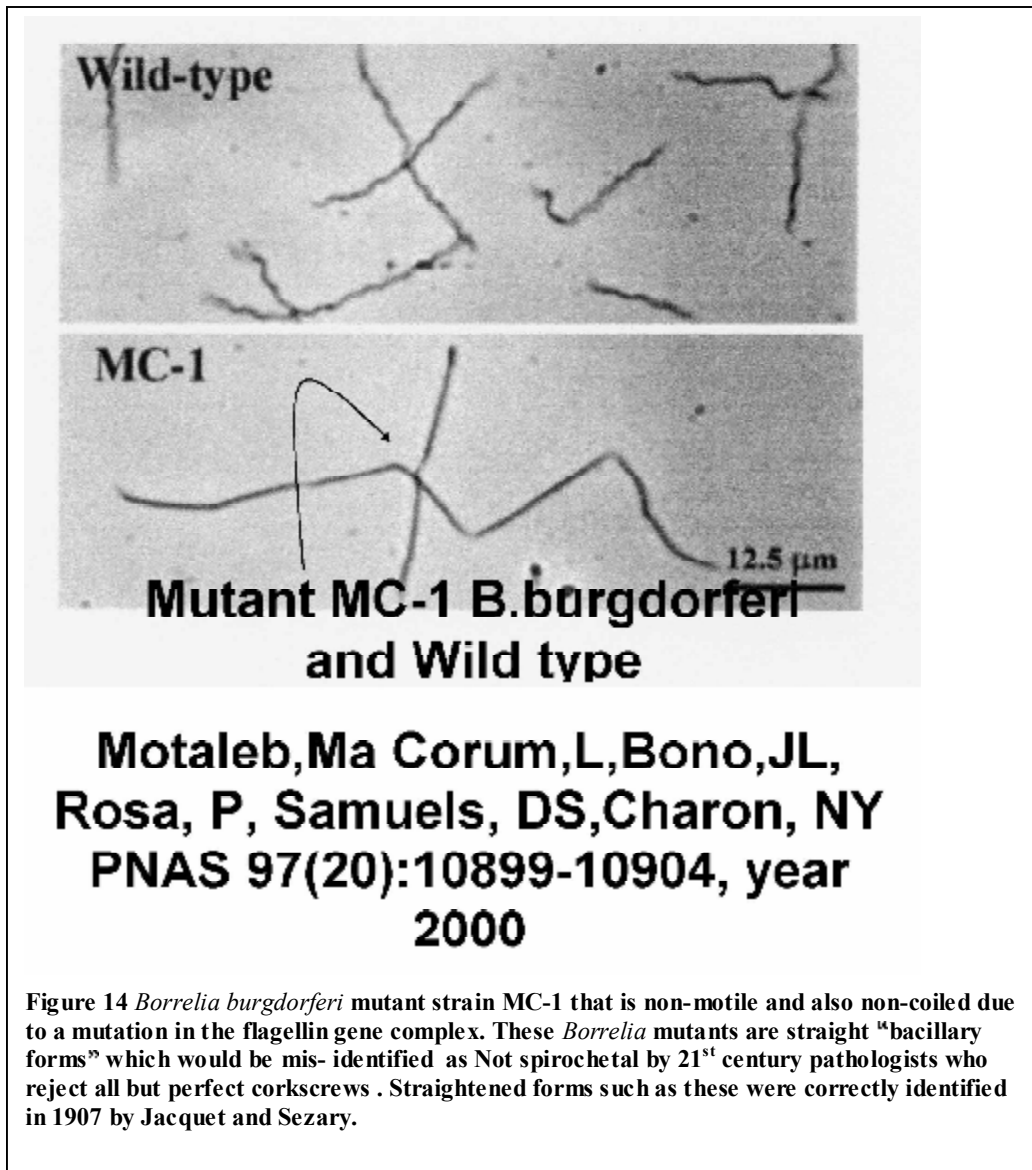
Figure 12 Periplasmic Flagellae of *Borrelia* detached from parent spirochete, from Aged culture of *Borrelia burgdorferi* ATCC 35210 (Strain B31) darkfield 1000x oil immersion with correction collar objective. Note the diminutive cross sectional diameters when compared with diameter of intact parental spirochetal forms above. Alan MacDonald MD, unpublished image.

Flagella-less mutants of *Borrelia burgdorferi* – strain HB19 –
American Type Collection reference 55131.

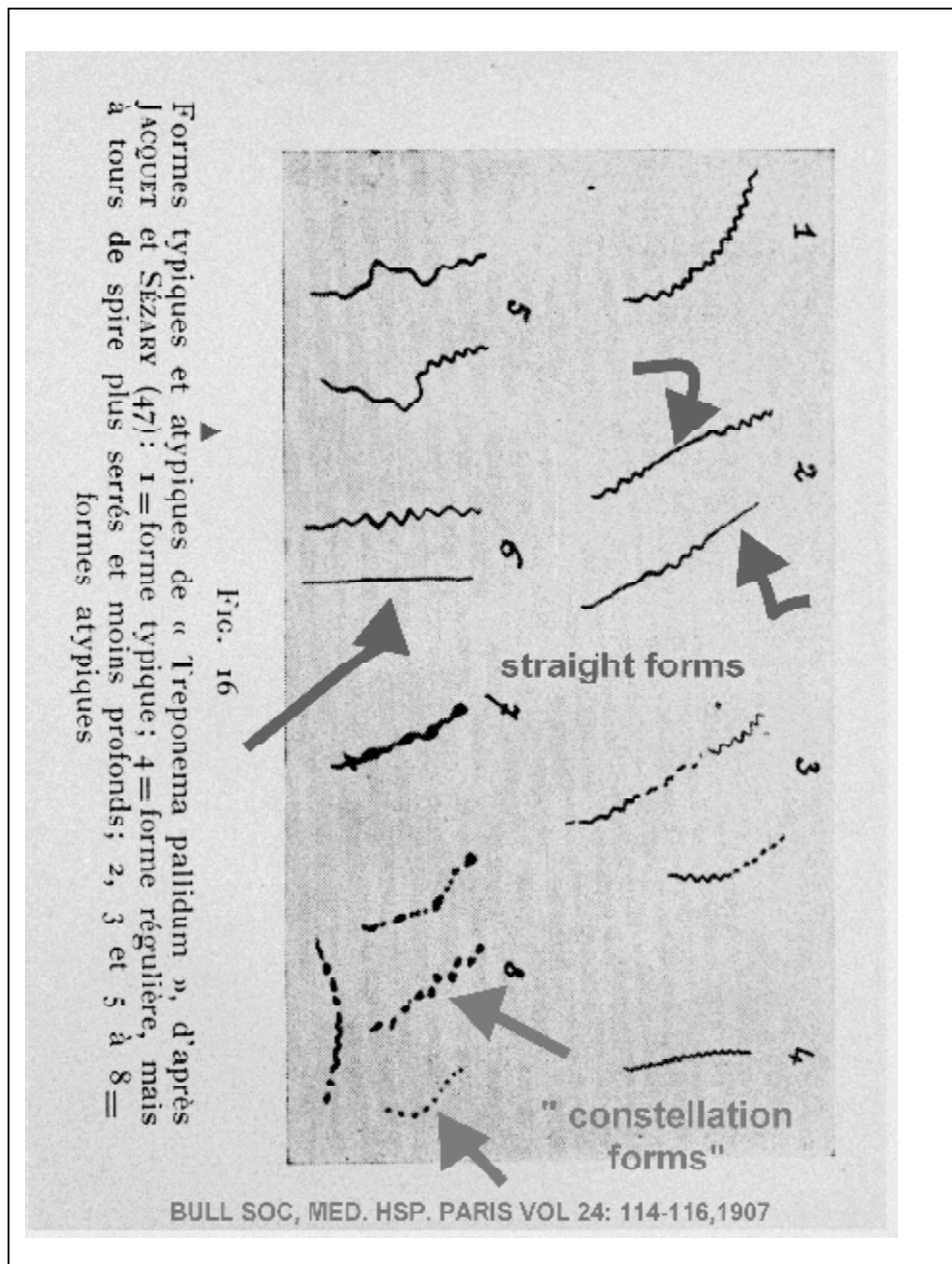


Flagella-less mutants of *Borrelia burgdorferi* – strain HB19 –

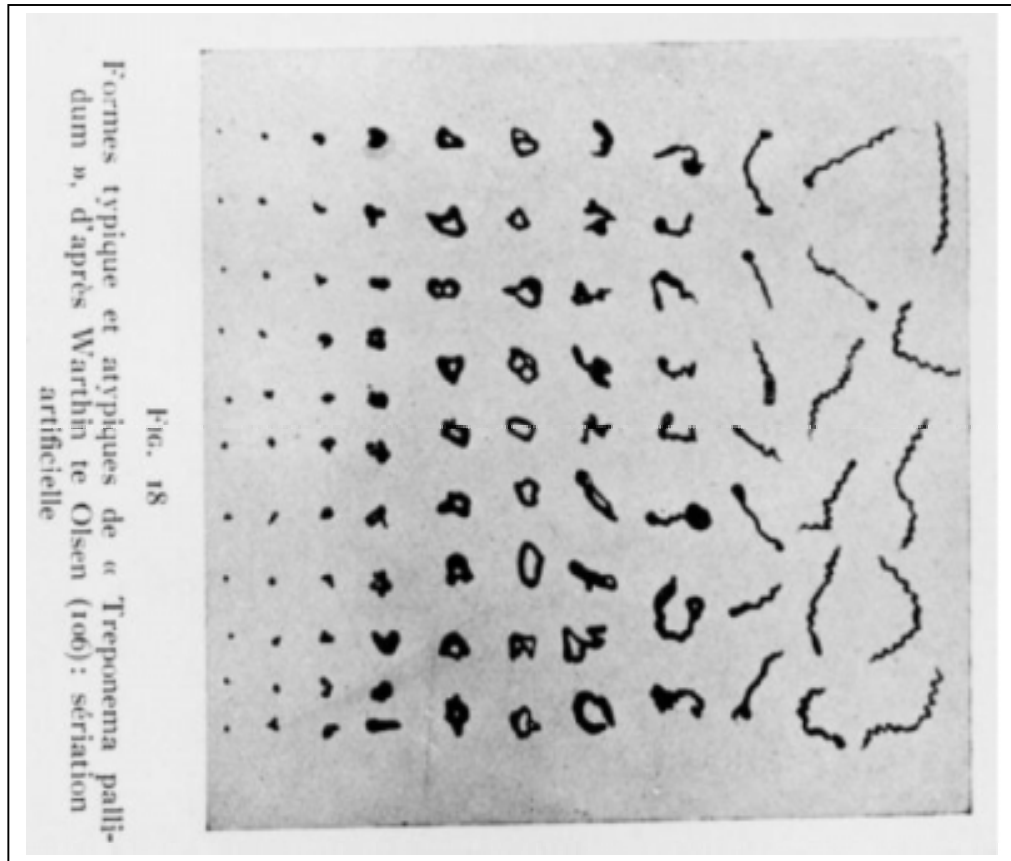
American Type Collection reference 55131.



Spirochetal Images from the early 20th century demonstrating Diverse morphology for *Treponema pallidum*.



Warthin and Olsen's 1930 tabulation of *Treponema pallidum* morphologies
in autopsy cases of Syphilitic aortitis.



Various examples of Intracellular pathogenic spirochetes:

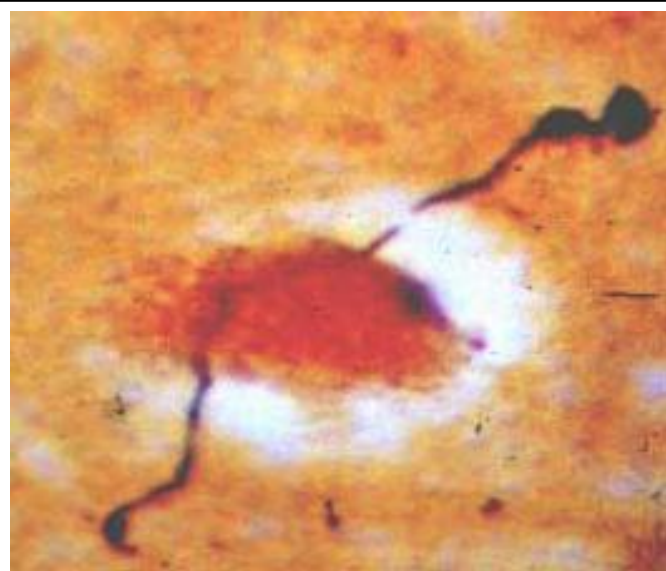


Figure 15 Spirochete traversing nerve cell nucleus in Fetal Autopsy brain. Gestational Lyme borreliosis study, 1989.

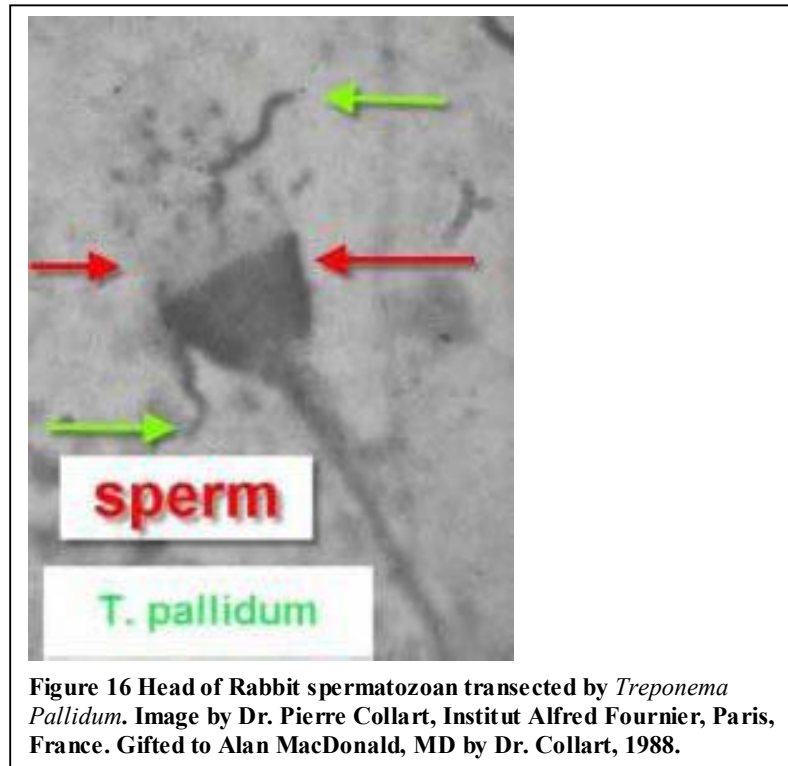
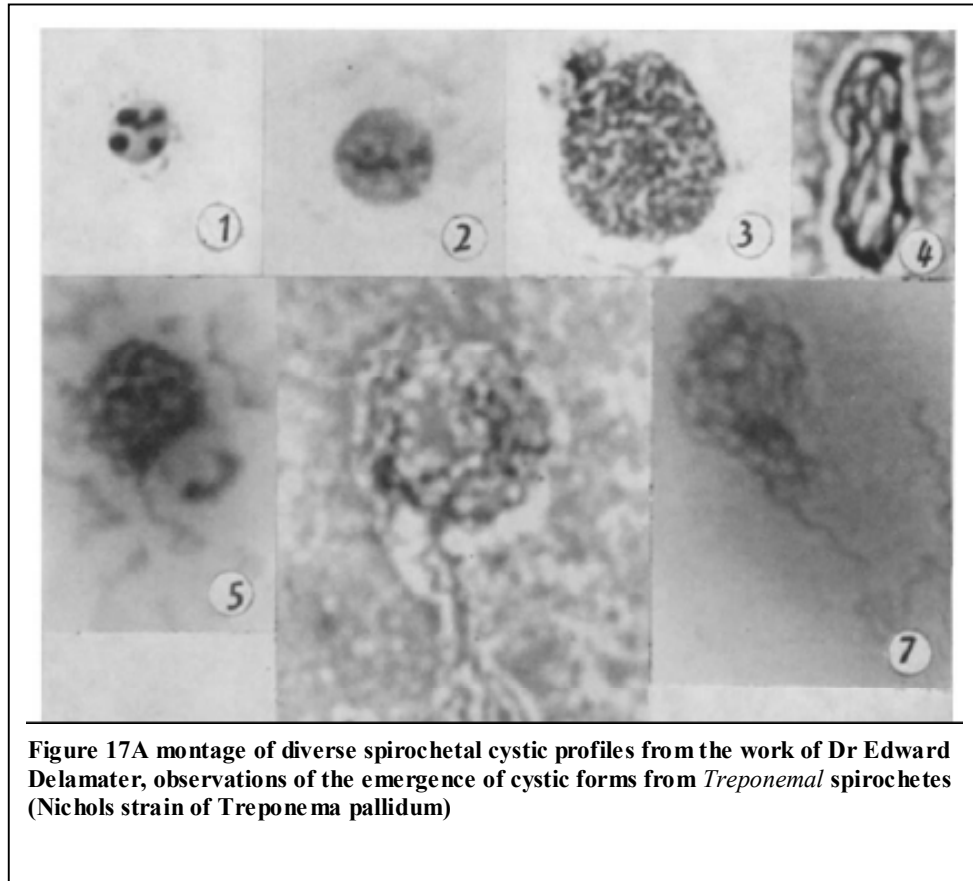


Figure 16 Head of Rabbit spermatozoan transected by *Treponema Pallidum*. Image by Dr. Pierre Collart, Institut Alfred Fournier, Paris, France. Gifted to Alan MacDonald, MD by Dr. Collart, 1988.

Cystic diversity of the Nichols strain of *Treponema pallidum* in the works
of Dr. Edward Delamater and colleagues, 1950.



Cystic diversity of the Nichols strain of *Treponema pallidum* in the works
of Dr. Edward Delamater and colleagues, 1950.

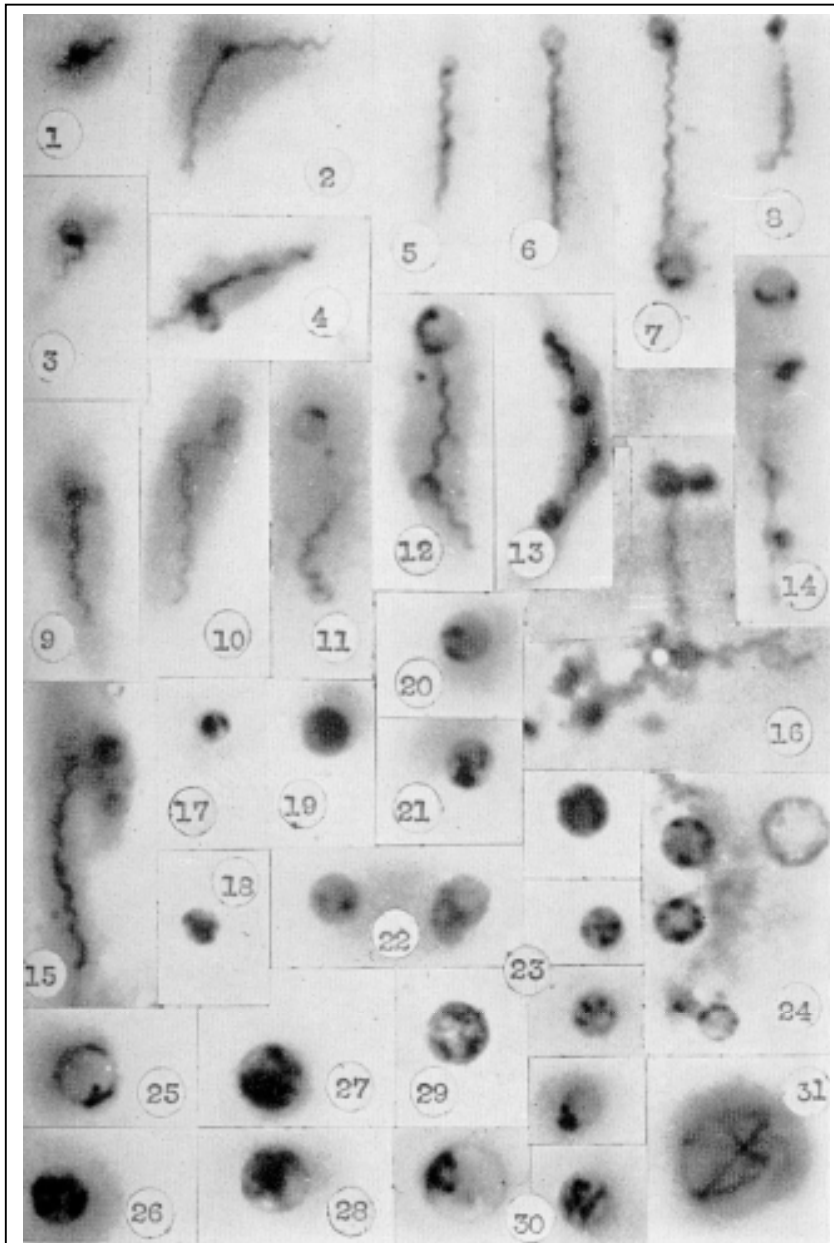


Figure 18 Montage of Cystic spirochetal forms derived from *Treponema pallidum* spirochetes, from Dr Edward Delamater and colleagues, 1950

Consequences of the Hypothesis:

A life cycle for spirochetes based on the spirochetal infective granule was defended by Balfour (1907), Breinl (1907),Dutton and Todd (1907),Leishman (1911),Fantham (1911),McDonagh (1912), Hindle (1912). The germinative ability of the minute dot-like granules and the contributions of the spherical cyst-like forms were implicated in life cycle diagrams which linked the development of corkscrew shaped spirochetes to infective granules. In the present 21st century "revision" the early 20th century models ; cystic and L form spirochetal elements are added , and membrane Blebs containing parasitic DNA were integrated into the infective granule life cycle model . This amalgamation produces a tripartite "Cyst-Bleb-Granule life cycle" which consists of three "arms". Each "arm" is capable of assaulting mammalian cells.

Pathologic studies correlate \ spirochetal mediated structural alterations in diseased tissues. When infection is a diagnostic consideration for the actual etiology of a disease process, it is the incumbent responsibility of the histopathologist to either confirm or to exclude the "infection hypothesis". Application of "special stains" which transform "invisible microbes" in diseased tissues into "visible" agents of tissue injury accomplish the first step in the correct classification process. The second step, namely seeing with the "frontal cortex" and interpreting the images, which are projected onto the retina, is only accomplished by the mind, which is prepared to recognize and interpret the retinal images. This is the difficult step. Each potential microbial pathogen should have its picture in the Atlas of "alleged perpetrators". A defined life cycle assists in this step.

Images contained within this manuscript offer a "new scaffold" namely a

Spirochete Life Cycle?

page 24

Life -cycle concept. Hopefully the life -cycle gallery of "legitimate " spirochetal profiles which is here presented. will assist in the correct classification of *Borrelia* related infectious diseases in mammalian hosts. The images herein are only intended to serve as a "primer" of the truly protean microscopic profiles which must be duly considered in the microscopic quest for pathogenic spirochetes in tissue.

Acknowledgements:

This work was supported by a research grant from the Turn the Corner Foundation, New York, New York and by generous Institutional support from St. Catherine of Siena Medical Center, Smithtown, New York .

References:

1. Schaudinn, F., Hoffman, S, "Über *Spirochaeta pallida* bei syphilis und die unterscheide dieser form gegenüber anderen Arten dieser Gattung" Berlin Klin. Wochschr. , 1905, 42: 673-5
2. Dutton, J.S., Todd, J.L., "A note on the morphology of *Spirochaeta Duttoni*", 1907, Lancet 2: 1523.
3. Breinl, A., "The morphology and life history of *Spirochaeta Duttoni*", No. 3., 1907, Annals of Tropical Med. and Parasitology.
4. Balfour, A., "A peculiar blood condition, probably parasitic in Sudanese Fowls", 1907, British Med Journal, Nov 9th, 1330-3
5. Leishman, W.B., "An Address on the mechanism of infection in tick fever, and on hereditary transmission of *Spirochaeta duttoni* in the tick", 1911, Lancet 133:11-14.
6. Fantham, H.B., "Some researches on the life-cycle of spirochetes", 1911, Annals of Tropical Med. and Parasitology, 5:479-96.
7. Balfour, A., "The infective granule in certain protozoan infection, as illustrated by the spirochetosis of Sudanese Fowl", 1911, British Medical Journal 1:752.
- 8 . McDonagh, JER, "The Life cycle of the organism of syphilis", 1912, Lancet:2:1011.
9. Hindle, E., "On the life-cycle of *Spirochaeta gallinarum*", 1912, Parasitology IV: 463-77.
10. Delamater, E.D., Hanes, M. Wiggall, R.H., "Studies on the life cycles of spirochetes: V. "The life cycle of the Nichols non-pathogenic *Treponema* in culture", 1951, American Journal of Syphilis 35:164-179.

References (Continued)

11. Rubel, Joanne, "Spirochetal Cysts, L-forms, and Blebs, Observations from 1905 to 2005", Web access, <http://www.lymeinfo.net/medical/LDBibliography.pdf> , date visited March 15,2006.
12. Steiner, G., "Morphology of *Spirocheta myelophthora* in Multiple Sclerosis", J. Neuropath. and Exp. Neurology, 1954, 13:221.
13. MacDonald, A.B., "Plaques of Alzheimer's disease originate from cysts of *Borrelia burgdorferi*, the Lyme disease spirochete", 2006, Medical Hypothesis, (In press)

Elsevier Editorial System(tm) for Medical Hypotheses

Manuscript Draft

Manuscript Number: YMEHY-D-06-00180R2

Title: Spirochetal cyst forms in Neurodegenerative disorders, ...hiding in plain sight

Article Type: FLA Full Length Article

Section/Category:

Keywords:

Corresponding Author: Dr. Alan B. MacDonald, MD

Corresponding Author's Institution: St Catherine of Siena Medical Center

First Author: Alan B. MacDonald, MD

Order of Authors: Alan B. MacDonald, MD

Manuscript Region of Origin:

Spirochetal cyst forms in Neurodegenerative disorders, ...hiding in
plain sight

Alan B. MacDonald, MD

St. Catherine of Siena Medical Center

Department of Pathology

50 Rte 25 A

Smithtown, New York

11787

USA

Telephone : 631-862-3764 (voice)

631-862-3863(fax)

email: inmacdonald@yahoo.com

Grant support: Turn the Corner Foundation, New York, New York

Abstract:

Here is proposed a hypothesis that a completely unsuspected biology exists for pathogenic spirochetes, namely that the cystic spirochetal forms (long thought to be static and resting or just a dormant cohort) actually are capable of killing mammalian host cells. At least two "lethal" scenarios are proposed; first, the host cell destruction from the "inside out" by small caliber cystic forms invading the host cell cytoplasm, and second host cell destruction by engulfment of entire host cells by large caliber cystic spirochetal forms.

Conventional thinking about spirochetal cyst forms is divided between two polar spheres of influence; one a majority community that completely denies the existence of spirochetal cyst forms, and a second group of academically persecuted individuals who accepts the precepts of such antebellum scientists as Schaudinn, Hoffman, Dutton, Levaditi, Balfour, Fantham, Noguchi, McDonough, Hindle, Steiner, Ingraham, Coutts, Hampp, Warthin, Ovcinnikov, and Delamater.

Microscopic images of cystic spirochetes are difficult to ignore, but as has been the case in this century, academic "endowments" have nearly expunged all cystic spirochetal image data from the current textbook versions of what is the truth about the Spirochetaceae. If the image database from the last century is obliterated; many opportunities to diagnose will be lost.

Various sized cystic spirochetal profiles within diseased nerve cells explain the following structures : Lewy body of Parkinson's disease, Pick body, ALS spherical body, Alzheimer plaque. Borrelia infection is therefore a unifying concept to explain diverse

neurodegenerative diseases , based not entirely on a corkscrew shaped profile in diseased tissue, but based on small, medium and large caliber rounded cystic profiles derived from pathogenic spirochetes which are . "hiding in plain sight".

Introduction:

Like Gaul, the kingdom of Spirochetes is divided into three parts: corkscrew, granular, and cystic. By way of historic chronology, Schaudinn and Hoffman in 1905, were the first to "see" *Treponema pallidum*, the syphilis spirochete. Darkfield microscopy, with its unique optics, rapidly revealed the structural diversities of pathogenic spirochetes (*Borrelia*, *Treponema*, and *Leptospira*). The "caricature" of the corkscrew form was not imposed on the minds of microscopists who dealt with the public health issues of Syphilis in its epidemic forms in the twentieth century. In the 21st century, most of the spirochetal wisdom of the past has been neglected and spirochetal profiles other than the corkscrew form are not accepted by academicians who have never personally used a darkfield microscope. Cystic spirochetal profiles are an indispensable intellectual benchmark in the life of Spirochetaceae, and constitute a cardinal point in the map of a complex life cycle, which rivals the life cycles of such protozoan pathogens as *Plasmodium* species which are the agents of various forms of malaria in the mammalian host.

When, in times past, it was acceptable to speak and to think about cystic spirochetes, discussions linked these spherical forms with the following: dormant infections, clinical latency, and relapse of infection after antispirochetal therapies with heavy metals had been completed. The "eradication" of syphilis after World War 2 decimated the ranks of

medical and basic science experts in the field of Syphilology, and a mass exodus to other fields of endeavor, including virology and immunology left a veritable “cosmic black hole” in spirochetal studies; of the type which extinguishes all light of spirochetal knowledge from the past.

Fortunately, in emulation of the monastic tradition, which preserved written academic works through the Dark Ages, a small number of workers have persevered and have endured persecution, to carry the light of knowledge of spirochetal cystic forms into this century. Recent advances in our understanding of the complexities of Lyme borreliosis, especially in its recalcitrant relapsing forms within the nervous system, have offered new “opportunities for improvement” in medical practice. Cystic forms of *Borrelia* have been identified in human spinal fluid from patients with Multiple Sclerosis, and a model has been proposed, based on rounded cystic *Borreliae*, to offer a radical redefinition of the true nature of the rounded Plaques which define Alzheimer’s disease. Other opportunities to find links to infection as the basis of various neurodegenerative disorders which are known by their rounded regions of injury in microscopic tissue studies, most notably Pick’s disease, with its intracytoplasmic “Pick bodies” are potential new applications for lost knowledge of cystic spirochetal profiles. Implicit in the theoretical “thread” which attempts to link such diverse entities as the Pick body inside of and the Alzheimer plaques outside of diseased nerve cells, is the concept that cystic spirochetes might “attack” and “destroy” human cells, rather than merely peacefully coexist with their neighboring cells.

The Hypothesis:

Cystic spirochetes constitute the actual agents of nerve cell injury for all of the following "named" entities in neuropathology: the Pick body, the "globular" Neurofibrillary tangle in Alzheimer's disease, the Alzheimer "amyloid" plaques, the Lewy bodies of Parkinson's disease, the Spherical Neuronal inclusion bodies of Amyotrophic Lateral Sclerosis, The Cortical Lewy bodies in Lewy Body dementia, and diverse rounded neuronal inclusions in other neurodegenerative diseases. Nerve cell injury is a consequence of the invasion of the healthy cytoplasmic compartment by "predatory" cystic spirochetes. Various rounded structures named "Pick", "Lewy", and "Spherical Neuronal inclusion" all represent a unified agent of injury; namely the cystic form of *Borrelia* spirochetes which have intruded inside the diseased nerve cells. Extracellular rounded zones of tissue injury such as "Alzheimer plaques" and "Extracellular Lewy bodies" actually represent profiles of larger caliber spirochetal cystic forms, some of which have ingested entire nerve cells to leave a "plaque" signature at the scene of the crime.

Evaluation of the Hypothesis:

In situ DNA hybridization using DNA probes optimized to detect spirochete specific DNA sequences, (which are not shared in the human genome) ,is the necessary tool to refute or to confirm the spirochete cystic attack model hypothesis. Molecular Beacons offer the most attractive technology for identifying “spirochetal signatures” by in situ DNA hybridization studies of human autopsy tissues.

Culture of fresh autopsy brain tissues for detection of spirochetal cystic profiles, and for detection of progressive increases of levels of spirochete DNA in the cultures offers a second pathway for evaluation of the cystic spirochete hypothesis.

Experimental infection of animals with material from diseased autopsy human brain specimens, (with the objective of reproducing the human disease in the animal model), is a potential third pathway to ratification or rejection of the spirochete cyst attack model.

The use of green fluorescent protein incorporated into the spirochetes grown in the laboratory is a potential fourth analytical pathway to evaluate the hypothesis in experimental animal inoculation studies. Green fluorescent protein is attractive as an analytical tool for the study of processes in living cells, because the fluorescent signals continue to be emitted from the labeled microbes reared in the laboratory, as they enter and reside within living cells.

Empiric Data:

Observations from the following experiments would seem to provide some support for the following:

1. Cystic forms of borrelia are capable of cell division in human spinal fluid without reversion to a corkscrew shaped form as an intermediary.

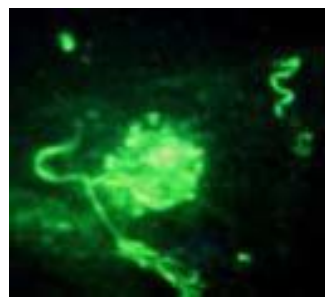
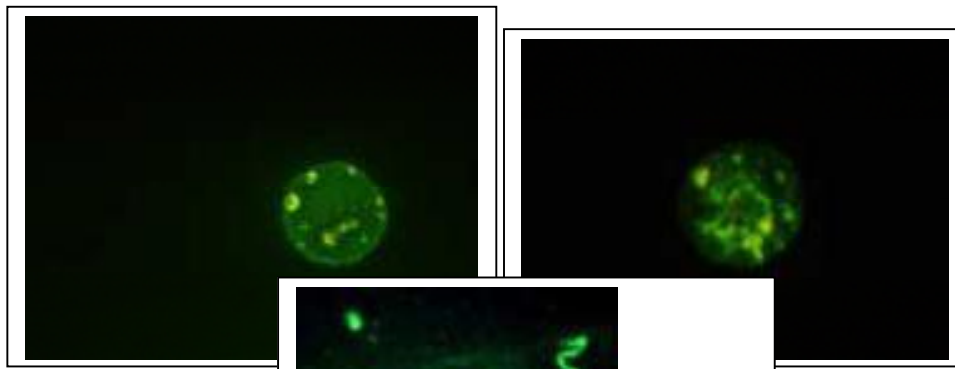


Figure 1: Cystic form of *Borrelia burgdorferi* with internal granules from B31 strain in culture in BCK medium for one year. Note residual attached conventional spirochetal form attached.

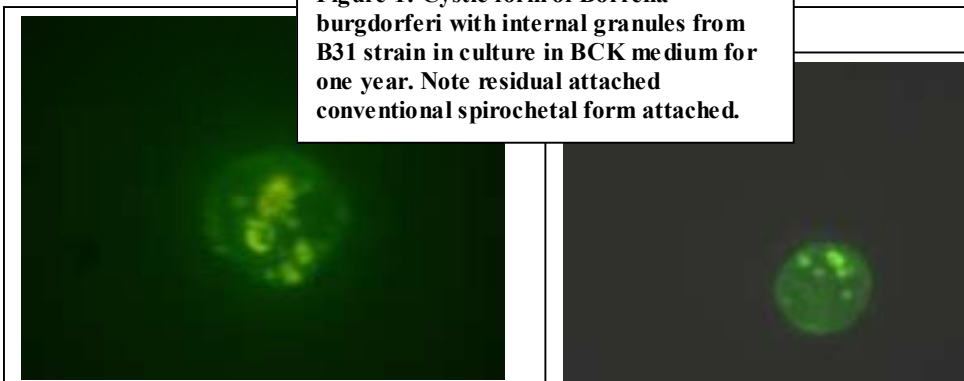

Figure 2- *Borrelia* cystic forms at positions 2,4,8,10 o'clock. Cultured from Human spinal fluid positive for *Borrelia burgdorferi* antibodies in Western blot. All routine cultures for other microbes negative at time zero and at 16 months of incubation in RPMI medium. Photo date February 2006, Alan B. MacDonald, MD.

2. Cystic forms of borrelia are present in pure laboratory in vitro cultures without invoking the "cyst induction" conditions of serum starvation, hypotonic osmotic shock, or environmental acidity (low pH), or antibiotic effects to promote the conversion of corkscrew forms into cystic spirochetes.

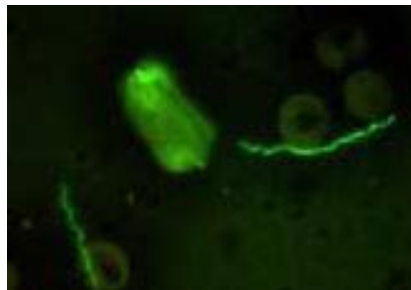


Figure 3-Cystic forms of Borrelia burgdorferi strain B31 in BSK culture in log phase growth, No adverse conditions implicated to induce "stress altered forms". Not conventional spirochetal forms . Note filamentous internal structure in the cystic form.

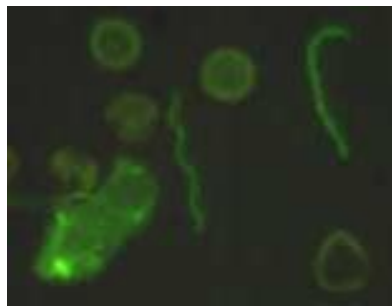


Figure 4 Caption similar to figure 3

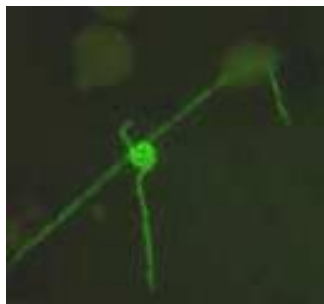


Figure 5- Caption similar to figure 4. Note smaller caliber cystic form containing an internally "rolled up" spirochetal form within the Cyst structure.

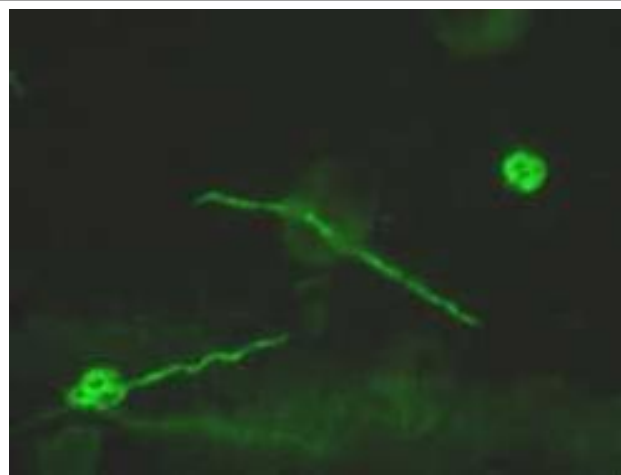


Figure 6- Caption similar to figure 5. Note spirochete traversing a red blood cell in the center of the screen.

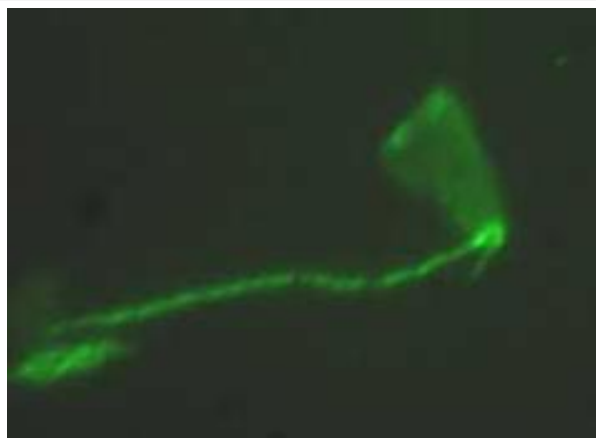


Figure 7 Caption similar to figure 4. Note the "trapezoidal" profile of the attached cystic form.

3. Cystic forms of borrelia may regenerate the corkscrew and granular spirochetal forms.




Figure 8- An Artist composite rendering of the conversion of corkscrew shaped *Borrelia burgdorferi* at 10 o'clock panel position to cystic forms in panels at 2, 5, and 7 o'clock positions. Note the internal "coiled" snake like profiles of the parent spirochetes. Reference Alban and Nelson.

4. Alzheimer disease tissue sections, in DNA staining methods with double labeling of Acridine orange and Oligreen stain for Single strand DNA (Invitrogen) demonstrate:

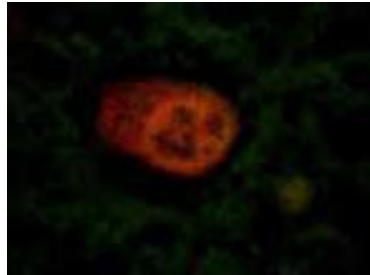

Figure 9 Tissue from Alzheimer autopsy hippocampus. Paraffin section. Nerve cell, healthy type, Acridine orange stain. 400x original magnification. Note rounded nucleus and cytoplasm staining red orange.

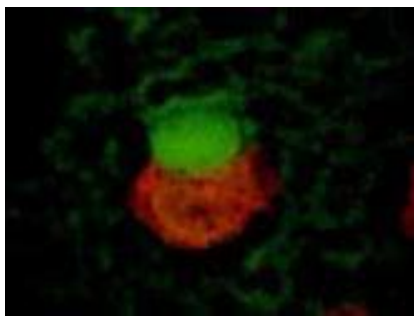


Figure 10- Alzheimer Autopsy hippocampus- Note green cystic form invading the cytoplasm of a nerve cell. Nucleus of the cell is at 6 o'clock position. 400 x original magnification. Alan B. MacDonald, MD.

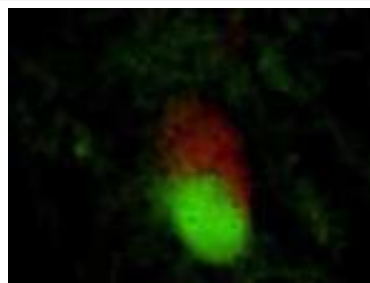


Figure 11 -Caption similar to figure 10. Green spirochetal cyst form at 6o'clock. Cell nucleus at 12 o'clock position.

5. Alzheimer disease Fresh brain fingerprint preparations demonstrates the “attack model” of spirochetal cystic forms with degenerating nerve cells of the Hippocampus:

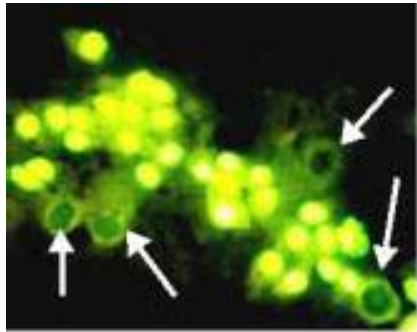


Figure 12 Alzheimer Autopsy hippocampus region CA1. Fresh tissue, fingerprint cytology monolayer. Note cystic spirochetal forms (arrows) approaching nerve cells. 400x magnification. Alan B. MacDonald, MD

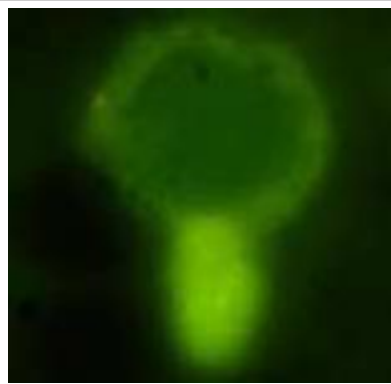

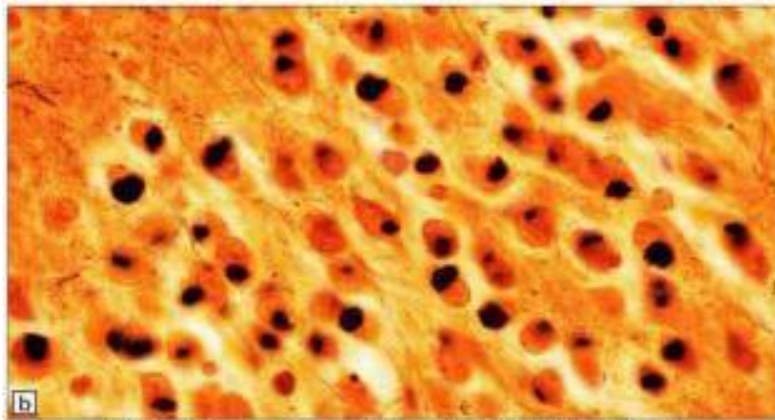
Figure 13-Caption similar to figure 12 above- large cystic spirochetal profile attached to remnant of nucleus of nerve cell.

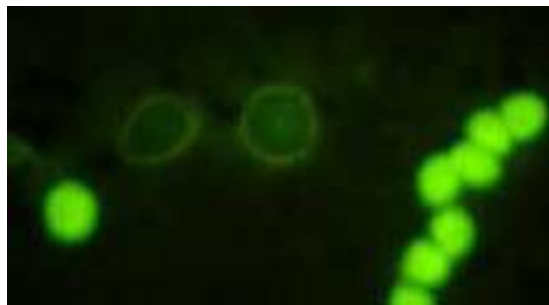

Figure 14-Caption similar to figure 12- Two cystic spirochetal forms between nerve cells of hippocampus region CA1. 400 x magnification. Alan B. MacDonald, MD

6. There is morphologic overlap between the profiles of the Pick body, Lewy body, Alzheimer Plaque, and the ALS spherical Neuronal inclusion body.

(All Images from Section 6 are from :Neuropathology, 2nd edition, pub 004, Mosby, Elsevier Publishers.)



Ellison & Love: Neuropathology 2e © 2004 Elsevier Ltd.

Figure 15-Pick bodies- Silver stain-(Bielschowsky) Hippocampus. Note rounded profiles inside diseased nerve cells.

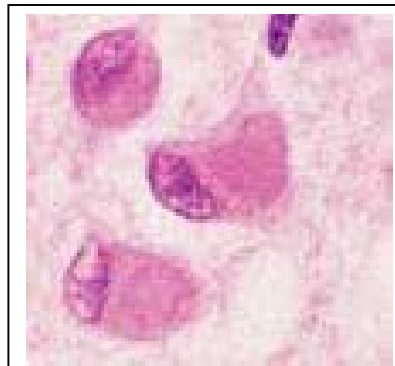
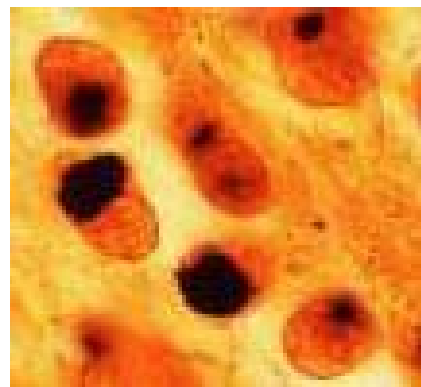
Figure 16-Pick bodies. 9 o'clock frame Silver stain, 3 o'clock frame hematoxylin and eosin stain. Note rounded profile inside nerve cells.


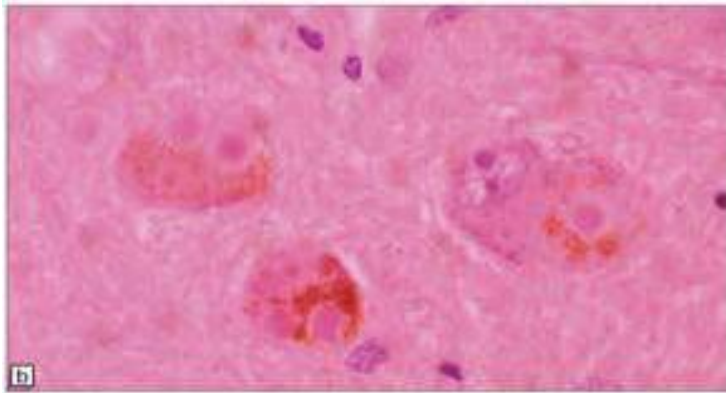


Figure 17-Compare Cystic Borrelia burgdorferi from Alzheimer brain imprint - Murine Monoclonal Antibody H9724 (Flagellin).



Ellison & Love: Neuropathology 2e © 2004 Elsevier Ltd.

Figure 18-Parkinson's disease- Classical Lewy bodies -Hyaline red core and pale halo zone- Multiple Lewy bodies-Some Lewy inside the nerve cell and some Lewy bodies OUTSIDE of the nerve cells. (arrows = outside Lewy bodies)

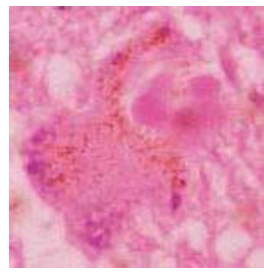
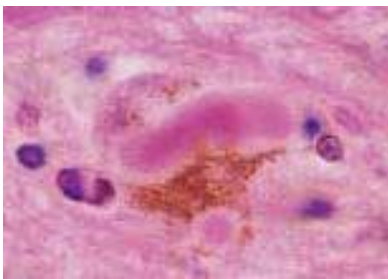
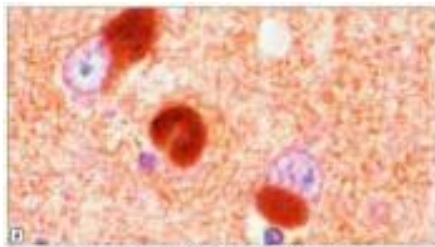
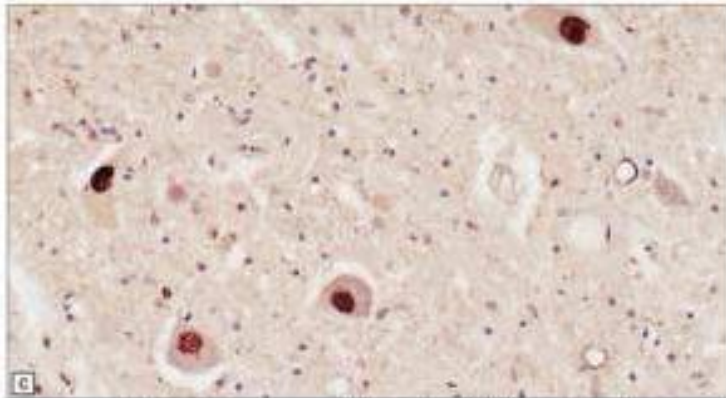


Figure 19-Parkinson's disease with VARIANT Lewy Bodies- (variant because of nonrounded contour)



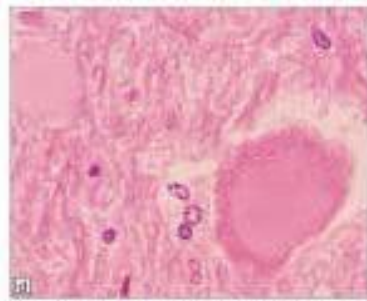
Ellison & Love: Neuropathology 2e © 2004 Elsevier Ltd.

Figure 20-Cortical Lewy bodies - Present in Cerebral cortex, as opposed to Parkinson's disease without dementia in which Lewy bodies are found in the Substantia nigra. Immunostain for Alpha synuclein- characteristic for Lewy body immunohistological profile.



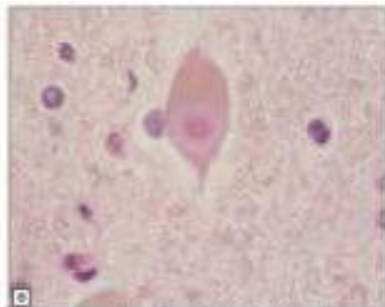
Ellison & Love: Neuropathology 2e © 2004 Elsevier Ltd.

Figure 21- Amotrophic Lateral Sclerosis (ALS)- Spherical inclusions inside nerve cells - so called "Lewy body like inclusions" - immunostain for ubiquitin.



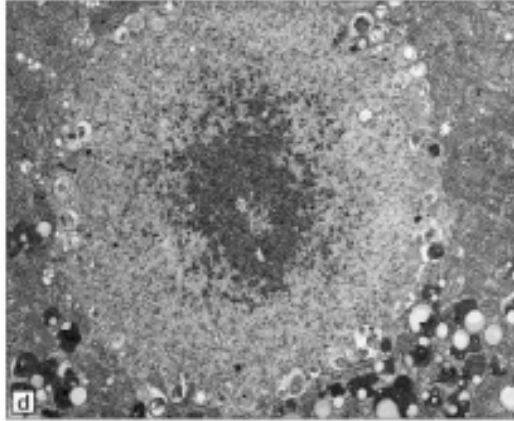
Ellison & Love: Neuropathology 2e © 2004 Elsevier Ltd.

Figure 22-ALS -rounded "hyaline" spherical intraneuronal inclusion.



Ellison & Love: Neuropathology 2e © 2004 Elsevier Ltd.

Figure 23- ALS - "uncommon" spherical inclusions "resemble the Lewy bodies seen in Parkinson's disease"- (dense central red core with a "halo")



Ellison & Love: Neuropathology 2e © 2004 Elsevier Ltd.

Figure 24-ALS -electron microscopy of spherical inclusion- " a relatively dense core and a peripheral zone of radially arranged FILAMENTS and GRANULAR material"

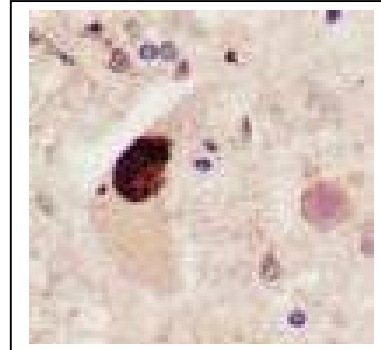
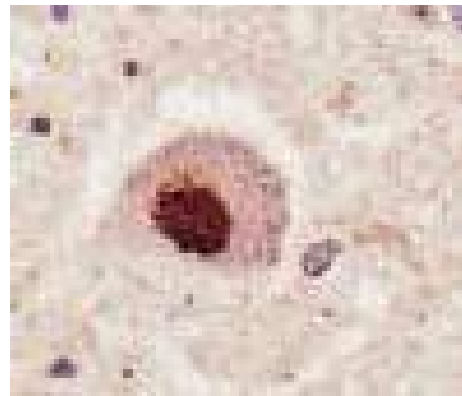


Figure 25-ALS spherical Inclusion- stained with Ubiquitin.

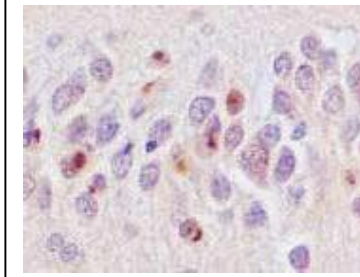
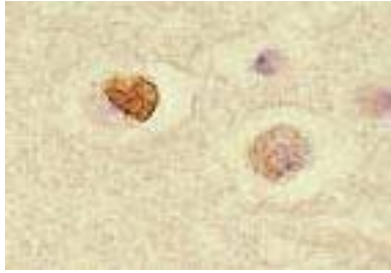
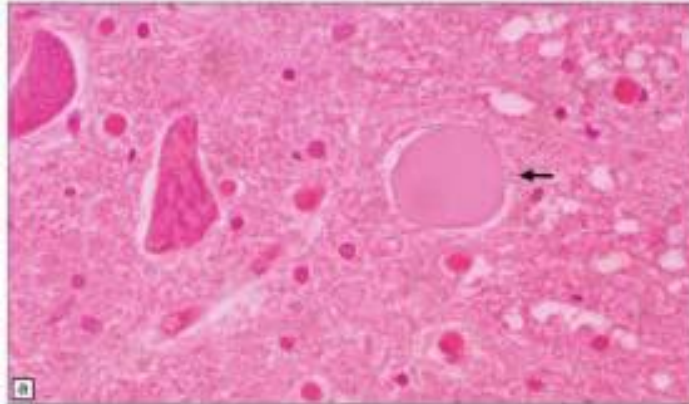


Figure 26-ALS - Inclusions in Nerves not dedicated to motor function. "Extra motor spherical inclusions in ALS"



Ellison & Love: Neuropathology 2e © 2004 Elsevier Ltd.

Figure 27-ALS - Axonal Spheroid in Anterior horn cell.

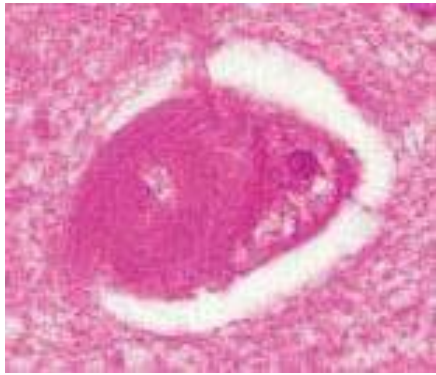
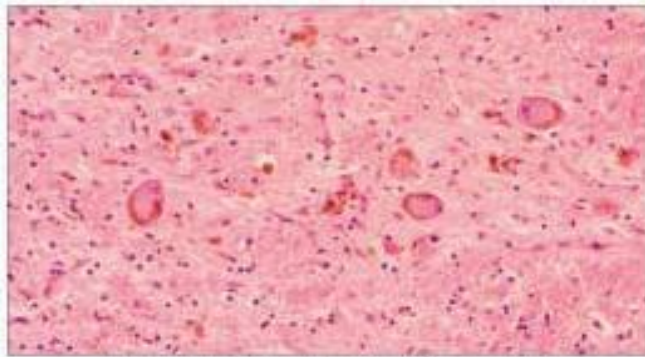


Figure 28-Alzheimer's disease - rounded "Globular" NFT material inside of Nerve cell (With a Filamentous profile)



Ellison & Love: Neuroanatomy 2e © 2004 Elsevier Ltd.

Figure 29-Corticobasal Degeneration (CBD) - with rounded neural inclusions

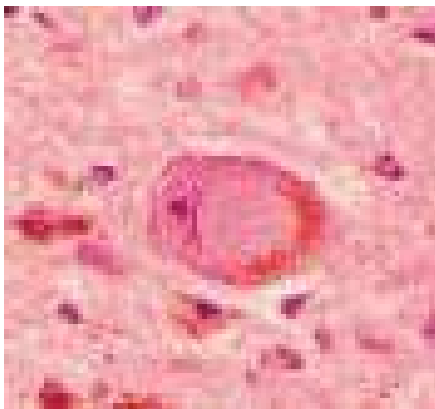
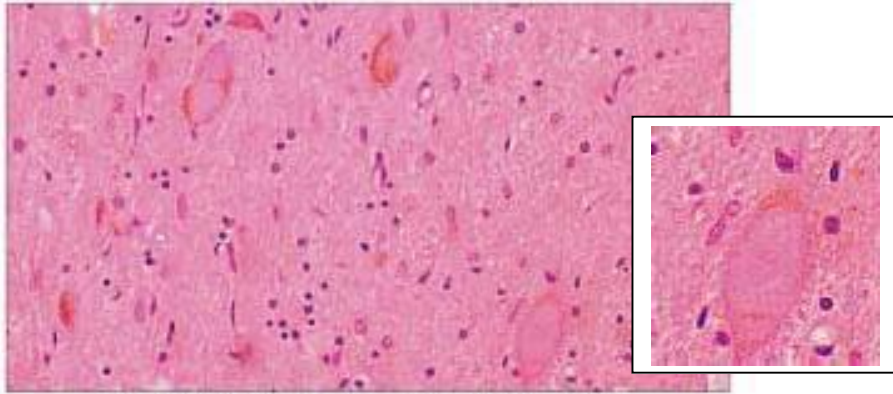
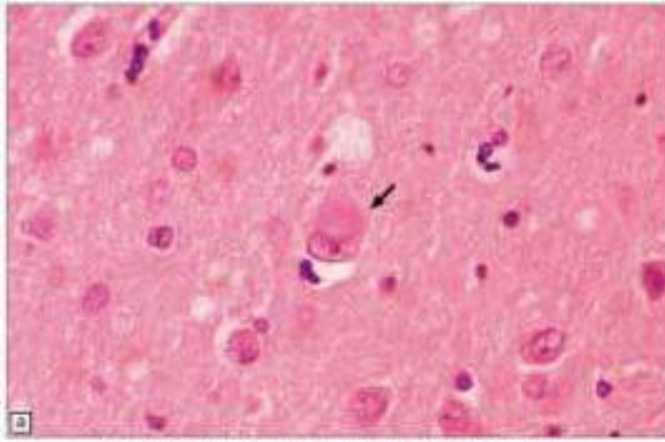


Figure 30- CBD - Nerve with rounded intracytoplasmic inclusion.



Ellison & Love: Neuropathology 2e © 2004 Elsevier Ltd.

Figure 31-CBD - Neuronal Inclusions in the substantia nigra



Elison & Love; Neuropathology 2e © 2004 Elsevier Ltd.

Figure 32-Cortical Lewy Bodies - in Lewy body dementia

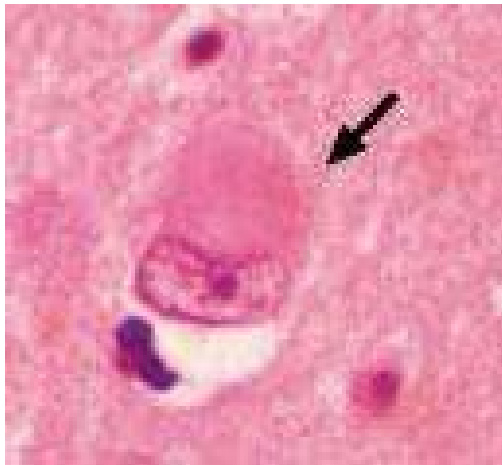
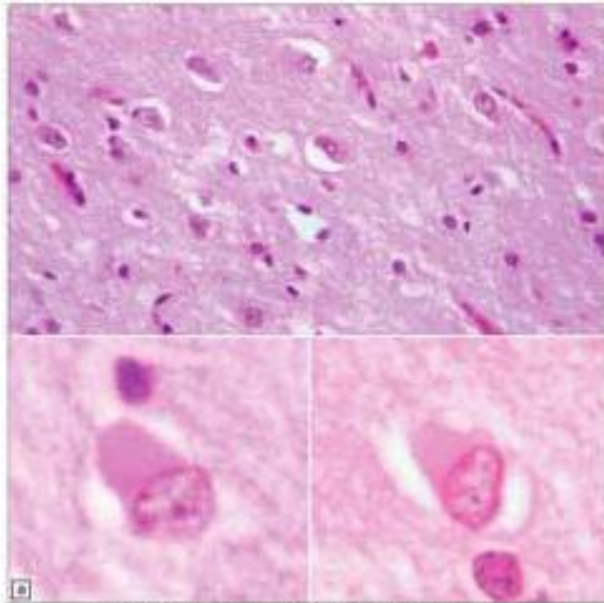


Figure 33-Cortical Lewy body in Lewy body Dementia

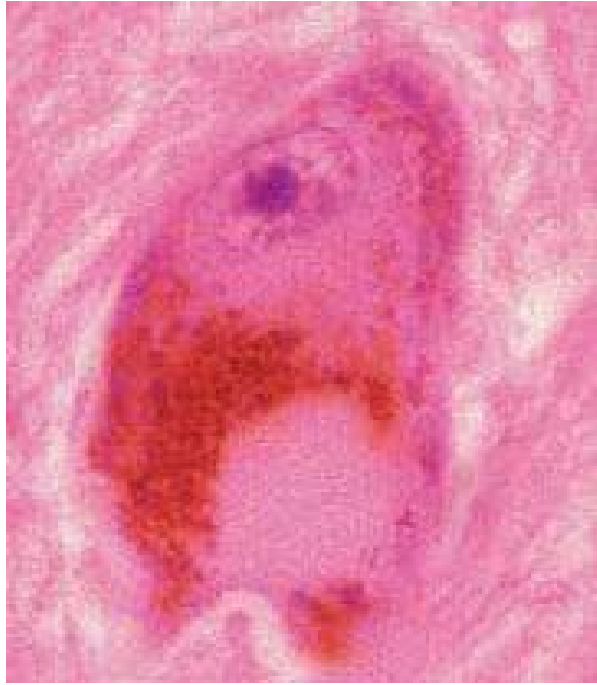

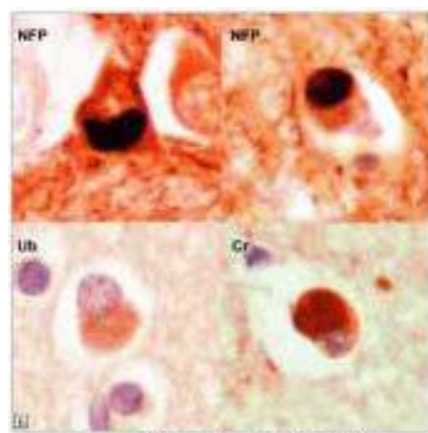
Figure 34-Parkinson's Disease - Lewy body Image and Paradigm.

Note the similarity to the spirochetal cyst form invading the nerve cell in figure 35 below. Lewy bodies and the assembled multitude of spherical bodies within diseased nerve cells in diverse neurodegenerative diseases, some with motor or movement disorders in patients without dementia and others with dementia- offer a conceptual bridge to implicate a single pathogenesis with a "cystic phenotype" and diverse "cystic genotypes" in the cystic cohort to explain diverse clinical neurological presentations. The only kindred conditions with such a wide array of clinical presentations which are all different manifestations of a similar route to pathogenesis is neurosyphilis.



Ellison & Love: Neuropathology 2e © 2004 Elsevier Ltd.

Figure 35-FLTD NF with rounded intraneural inclusions



Ellison & Love: Neuropathology 2e © 2004 Elsevier Ltd.

Figure 36-FLTD NF . Diverse markers for the intraneural rounded bodies , NFP = neurofibrillary protein, Ub= Ubiquitin, Cs= alpha beta crystallin

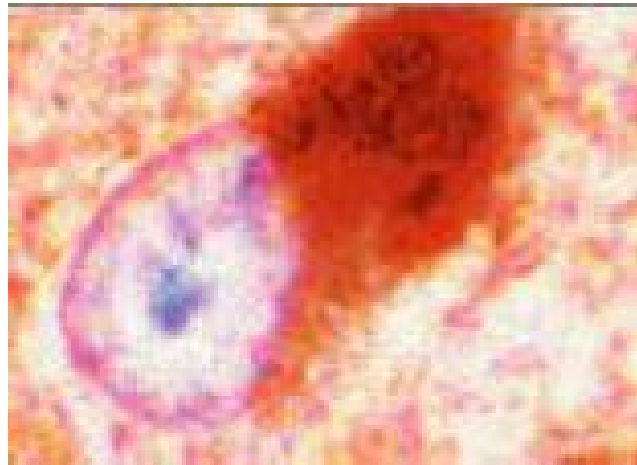


Figure 37- A diseased nerve cell with a rounded inclusion inside its cytoplasmic compartment- the origin of the inclusion is obscure with current knowledge

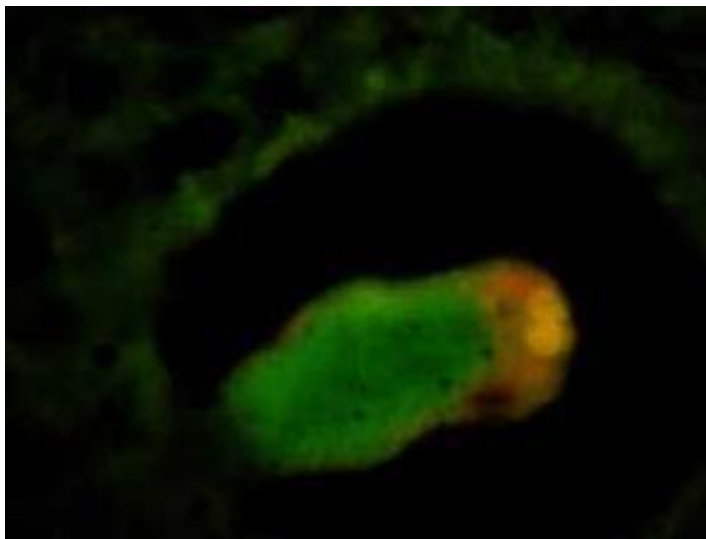
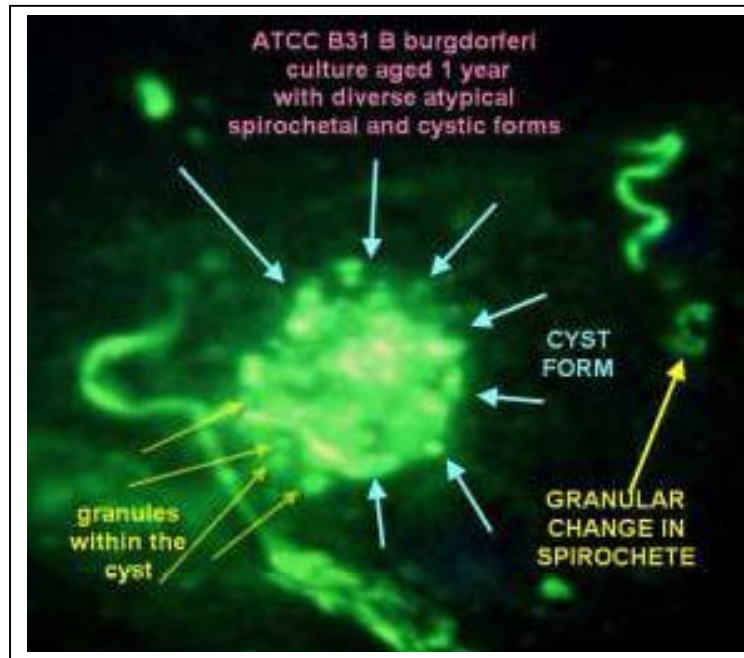
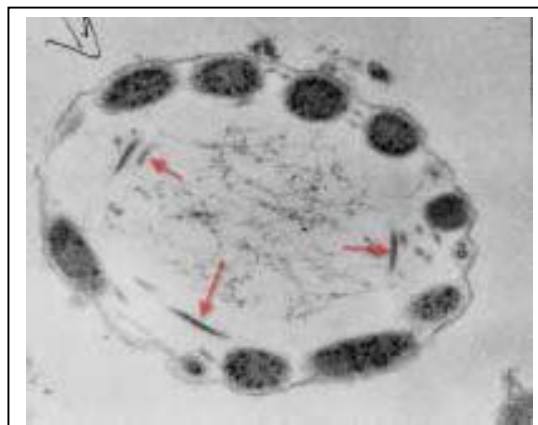


Figure 38- Alzheimer's disease hippocampal neuron (red) assaulted by a spirochetal cyst form. the Origin of the inclusion is a cystic spirochetal form

7. . Spirochetal cyst forms frequently demonstrate granular internal content.



8. Spirochetal cyst forms regularly demonstrate filamentous internal profiles.



9. Cystic forms of spirochetes include a cohort of cysts with amorphous internal structure.

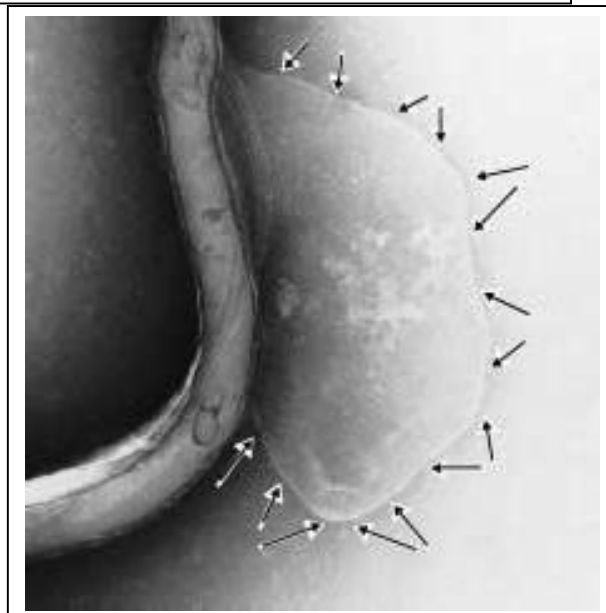
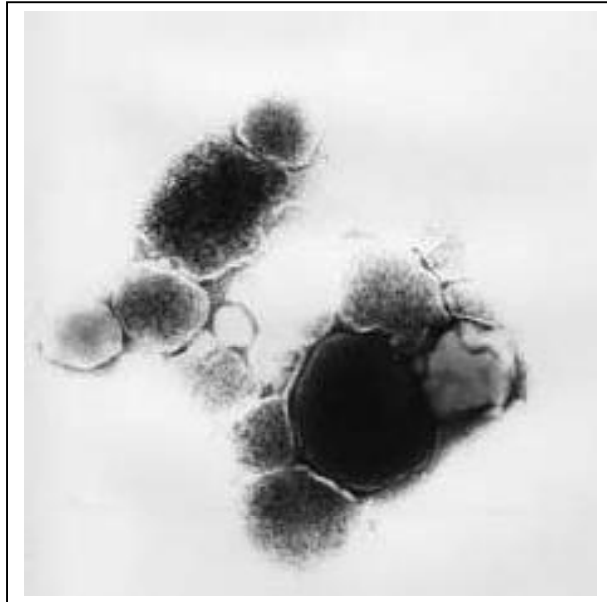
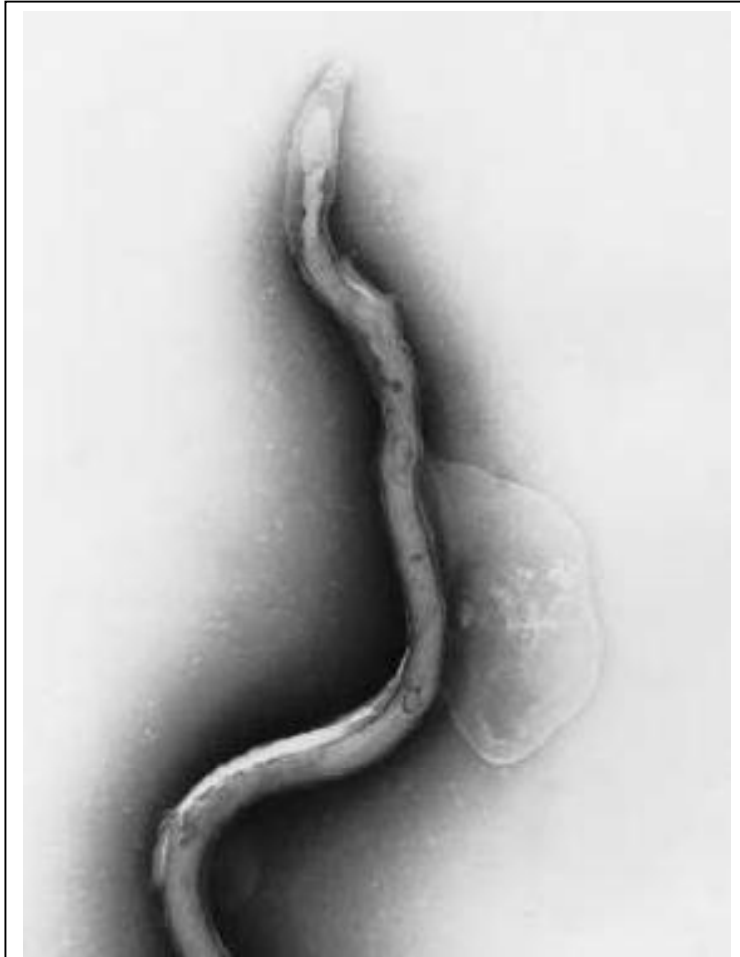



Figure 39-Cyst form evolving from corkscrew shaped *Borrelia burgdorferi*.

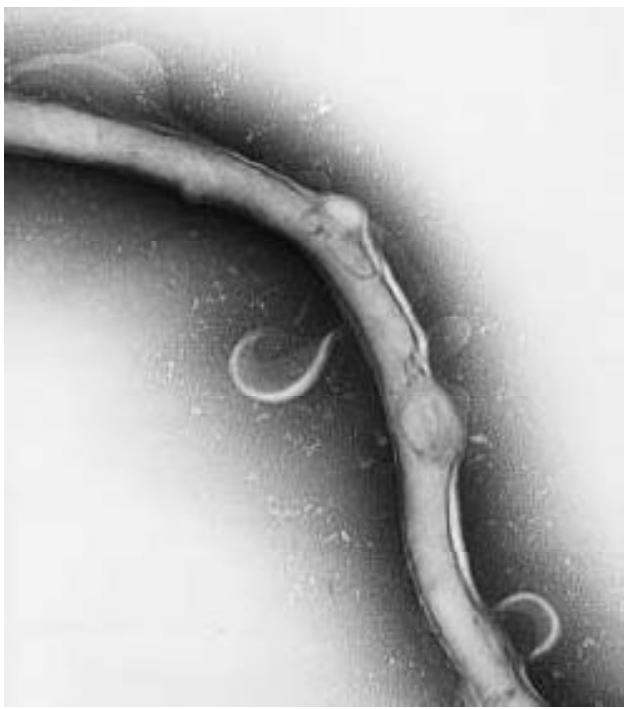

Figure 40- Caption same as figure 39.

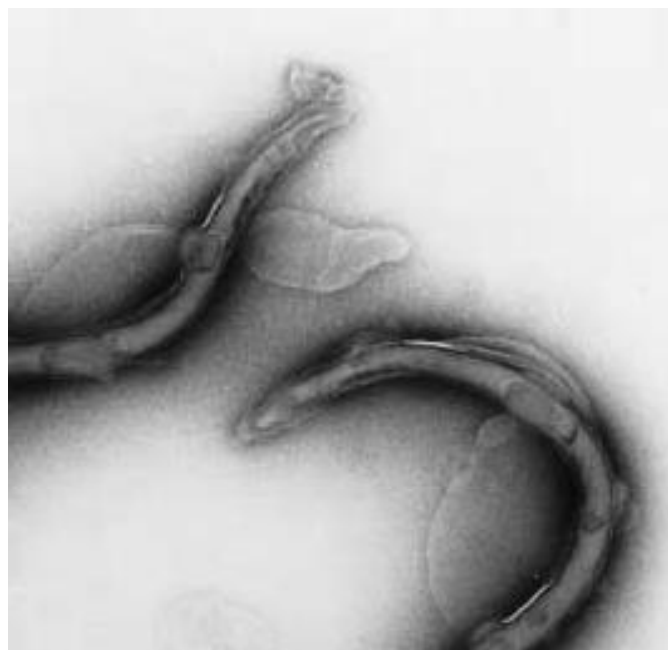

Figure 41-Caption same as Figure 39

Consequences of the Hypothesis:

If the spirochete cyst model is ratified, then multiple “neurodegenerative disorders” might be redefined as infection related illnesses. Unification of diverse diseases of the nervous system would require that textbooks be rewritten and that diagnostic procedures be revised to accommodate the early detection of *Borrelia* infections. Diagnostic evaluation of the spinal fluid would resume in earnest. Academic physicians would redirect their attention from postmortem immunostains for Tau protein and Alpha synuclein, to ante mortem evaluations of the diverse “attack models” for spirochetal infection in the nervous system. An entire cadre of neuropathologists and neurologists would need to be re-introduced to spirochetal related injuries of the brain, spinal cord and peripheral nervous system. Antispirochetal therapies would ameliorate, or even offer a prospect of cure for many of the “so called neurodegenerative diseases”. Dr. Hideyo Noguchi’s genius would be again lauded 100 years after his works to connect a persistent spirochetal infection with Dementia emerging after decades of latency. And dimly perceived” shadows on the wall of Plato’s cave would be relocated from the “column entitled degenerative” to find a new home in the discipline of Infectious disease medicine.

Acknowledgments:

This work was supported by a research grant from the
Turn the Corner Foundation, New York New York.

Generous institutional support was provided by the
St. Catherine of Siena Medical Center, Smithtown, New York.

References:

1. MacDonald, A.B., "Plaques of Alzheimer's disease originate from cysts of *Borrelia burgdorferi*, the Lyme disease spirochete", Medical Hypothesis, 2006 in press.
2. MacDonald, A.B., "A life cycle for *Borrelia* spirochetes", Medical Hypothesis, 2006, in press.
3. Rubel, Joanne, "Studies on Morphologic Variation in Spirochetes", <http://lymerick.ulmar.dk/2001-Bibliography-Alternate-Forms-spirochetes.pdf> , most recently visited April 1, 2006.
4. Anonymous , "Survival in Adverse Conditions- the Strategy of Morphologic Variation in *Borrelia burgdorferi* and Other Spirochetes 1900-2001" <http://lymerick.ulmar.dk/2001-AdverseConditions.pdf> , most recently visited April 1, 2006.
5. Anonymous, "Spirochetal Cysts, L-Forms, and Blebs, Observations from 1905 to 2005" <http://www.lymeinfo.net/medical/LDbibliography.pdf#search='spirochetal%20cysts'> most recently visited April 1, 2006.

Elsevier Editorial System(tm) for Medical Hypotheses

Manuscript Draft

Manuscript Number: YMEHY-D-06-00644

Title: Alzheimer's Neuroborreliosis with trans-synaptic spread of infection and neurofibrillary tangles derived from intraneuronal spirochetes

Article Type: FLA Full Length Article

Section/Category:

Keywords:

Corresponding Author: Dr. Alan B. MacDonald, MD

Corresponding Author's Institution: St Catherine of Siena Medical Center

First Author: Alan B. MacDonald, MD

Order of Authors: Alan B. MacDonald, MD

Manuscript Region of Origin:

Abstract:

Abstract:

In the realm of dementia, it is astonishing to note that neurofibrillary tangles (NFT) are microscopically identical in a childhood illness (SSPE) and in a dementia of late adult life (Alzheimer's disease). The words "Alzheimer-type" NFT in peer reviewed scientific articles written by acknowledged experts underscore the striking similarities in "tangles" two different diseases. SSPE (Subacute Sclerosing Panencephalitis) is caused by infection with atypical measles virus. Alzheimer's disease has no known cause.

There is little controversy in suggesting that all of the Tangles in SSPE infected neurons are produced by slow viral type variant of Measles infection. But the mere suggestion that infection might be a cause of Alzheimer's disease confounds the establishment. If a good case is to be made for infection in Alzheimer's disease, an excellent nerve cell infection model is needed. Monkeys have provided a very reasonable model. Recently, a primate neuroborreliosis brain infection model demonstrated that *Borrelia* injected into the skin of monkeys resulted the appearance of *Borrelia* transcriptomes in brain neurons. If *Borrelia* can travel from skin to brain in the monkey, then why not look at human Alzheimer's tissues to see if the DNA of *Borrelia* is present in the human brain? The molecular detection tools perfected in animal neuroborreliosis studies have been applied to human Alzheimer's disease brain tissues. Seven of ten cases of Alzheimer's disease from McLean Hospital Brain Bank of Harvard University yielded positive signals for infectious DNA in a small pilot study. Alzheimer's diseased neurons analyzed with DNA probes, produced little "dots" of positive staining. Granulovacuolar bodies in Alzheimer's diseased neurons (little dots in a bubble), is one of the expected microscopic profiles of Alzheimer's disease. The analogy of "little dots" inside infected nerve cells also represent viral infectious agents inside of nerve cells. So with the assistance of the microscope and the tools of molecular

biology, a new model of infection emerges as a cause of "Alzheimer's - type" neurofibrillary tangles. Here I hypothesize that it is chronic infection of human neurons in Alzheimer's disease that produces neurofibrillary tangles by a pathway similar to the chronic SSPE infection tangle pathway. In addition, transmission of infection from nerve to nerve is proposed to explain the evolution of Alzheimer's disease .Herein is offered a new view for the origins and for the progression of diseased nerves with tangle formations in Alzheimer's disease based on infection.

August 20, 2006
Dr Bruce Charlton
Editor in Chief
Medical Hypotheses

Re: Manuscript submission
"Nerve to nerve transmission of Borrelia infection in Alzheimer's disease and
"Infectious type Alzheimer neurofibrillary tangles" in the tradition of SSPE"

Dear Dr Charlton,

I submit for your consideration the above captioned manuscript.

I attest to the following:

1. The work is original.
2. This manuscript has not been previously submitted elsewhere.
3. I have no financial interest in the content of the manuscript
4. In the event that the manuscript might be considered for

publication in Medical Hypotheses, I agree to abide by the copyright
transfer procedures which are the policy of Elsevier Publishers.

With thanks and kind regards,

Alan B. MacDonald, MD
email: inmacdonald@yahoo.com

Alzheimer's Neuroborreliosis with trans-synaptic spread of infection
and neurofibrillary tangles derived from
intraneuronal spirochetes

Alan B. MacDonald, MD
Department of Pathology
St Catherine of Siena Medical Center
50 Rte 25 A
Smithtown, New York 11787

Telephone 1 631-862-3764 voice
FAX 1 631-862-3863
email address: inmacdonald@yahoo.com

Grant Support: Turn the Corner Foundation, New York, N. Y., USA.

Abstract:

In the realm of dementia, it is astonishing to note that neurofibrillary tangles (NFT) are microscopically identical in a childhood illness (SSPE) and in a dementia of late adult life (Alzheimer's disease). The words "Alzheimer-type" NFT in peer reviewed scientific articles written by acknowledged experts underscore the striking similarities in "tangles" in two different diseases. SSPE (Subacute Sclerosing Panencephalitis) is caused by infection with atypical measles virus. Alzheimer's disease has no known cause.

There is little controversy in suggesting that all of the Tangles in SSPE infected neurons are produced by slow viral type variant of Measles infection. But the mere suggestion that infection might be a cause of Alzheimer's disease confounds the establishment. If a good case is to be made for infection in Alzheimer's disease, an excellent nerve cell infection model is needed. Monkeys have provided a very reasonable model. Recently, a primate neuroborreliosis brain infection model demonstrated that *Borrelia* injected into the skin of monkeys resulted in the appearance of *Borrelia* transcriptomes in brain neurons. If *Borrelia* can travel from skin to brain in the monkey, then why not look at human Alzheimer's tissues to see if the DNA of *Borrelia* is present in the human brain? The molecular detection tools perfected in animal neuroborreliosis studies have been applied to human Alzheimer's disease brain tissues. Seven of ten cases of Alzheimer's disease from

McLean Hospital Brain Bank of Harvard University yielded positive signals for infectious DNA in a small pilot study. Alzheimer's diseased neurons analyzed with DNA probes, produced little "dots" of positive staining. Granulovacuolar bodies in Alzheimer's diseased neurons (little dots in a bubble), is one of the expected microscopic profiles of Alzheimer's disease. The analogy of "little dots" inside infected nerve cells also represent viral infectious agents inside of nerve cells. So with the assistance of the microscope and the tools of molecular biology, a new model of infection emerges as a cause of "Alzheimer's - type" neurofibrillary tangles. Here I hypothesize that it is chronic infection of human neurons in Alzheimer's disease that produces neurofibrillary tangles by a pathway similar to the chronic SSPE infection tangle pathway. In addition, transmission of infection from nerve to nerve is proposed to explain the evolution of Alzheimer's disease .Herein is offered a new view for the origins and for the progression of diseased nerves with tangle formations in Alzheimer's disease based on infection.

Introduction:

Too many neurofibrillary tangles in too many neurons in demented persons in the 7th, 8th and 9th decades of life is, on a statistical basis, Alzheimer's disease until proven otherwise. Such a provocative declaration is offered to call attention to the necessity of

"tangles" in Alzheimer's disease. (ref 1,2,3) If the root cause for the overabundance of tangle bearing neurons could be known, then opportunities for early diagnosis, treatment, and possibly eradication of Alzheimer's disease would exist. The arena of "tangles" is cluttered with enigmas and paradoxes. There is the paradoxical observation that a few tangles in the elderly brain do not produce dementia. We do not know what the upper "healthy limit" of tangle number might be. We do know that normal pediatric brains never have any tangles in neurons. Therefore, the opportunity to study a pediatric dementia with neurofibrillary tangles (SSPE) (ref 4,5,6) is a perfect occasion to observe an "assembly line" for pure neurofibrillary tangles, without any of the other contributions from the "Elderly brain". This concept might be restated by imagining two different assembly lines to tangle formation. In the pediatric patients and in young adults with SSPE infection where tangles are present the pathology findings are similar.(ref 7,8,9) In the Elderly Alzheimer brain, two possible assembly lines to tangle formation might be present. The first is the "old age" assembly line. This functions in all senior citizens to produce just a few tangles, but not so many tangles as to produce dementia. These are

the "background benign tangles" of senior citizens who are not demented. (ref 10) Elderly persons with Alzheimer's disease, however, have "too many tangles". The excess of tangles is herein postulated to come from the extra contribution of an second assembly line pathway due to nerve infection.

Two possible pathways to tangle formation establish a rationale for two clinical pathways in the senior citizen. To paraphrase the poet Robert Frost, "The road less travelled by ..makes all the difference". Two roads to tangles eliminate the confusion and the *Paradox of a few tangles with no dementia*. In healthy elderly patients without dementia the infection pathway is absent. Total "tangle burden" in the brain is a manageable condition..

The next issue for discussion in tangle development is the variable the duration of time that neuron infection is present in any individual. Short term versus long term infection are two choices on this menu. Again, there are lessons in the examples of SSPE in childhood. The "short duration" SSPE cases proceed to death in less than one year from the onset of symptoms. "Long duration" SSPE cases demonstrate chronic illnesses with dementia and survivals in excess of one year to many

years.

What pathology evidence exists for SSPE to prove that infection is indeed persistent? Chronic SSPE brain infection is caused by a variant paramyxovirus (Atypical measles).(ref 11,12,13,14) There is also an example of another virus (JK virus) which causes tangles after long term infection. Progressive multifocal leukoencephalopathy follows the clinical course of SSPE. This virus, like SSPE persists inside of infected neurons as tangles are produced. The electron microscope photographs prove that the viral agent (JK virus) continues to exist in tangle infested brain neurons right up to the death of the patient.(ref 15) Photographs of virus inside diseased cells early in SSPE and late in SSPE conclusively prove persistent chronic long term residence of an intracellular pathogen. (ref 16, 17)

Other authors' commentaries on comparisons between Alzheimer's disease and SSPE are excerpted from the medical literature in the following categories:

1. SSPE is the equivalent to ***"Alzheimer's disease lacking amyloid plaques and granulovacuolar degeneration" (ref 18)***
2. SSPE is a disease which is ***"indistinguishable"*** from Alzheimer's

disease by electron microscopic findings. **(ref 19)**

3. SSPE is a special example of an infection in which **"..neurofibrillary tangles can occur independently of amyloid formation."**.. and **"..this mechanism may operate in both Alzheimer's disease and virally induced disease.."**(ref 20)

4. SSPE is an example of a disease with **"..Tau positive tangles and neuropil threads similar to Alzheimer's disease..."** (ref 21)

Indeed, with so many parallels between SSPE Tangles and Alzheimer's disease tangles, how is it possible that the "tangled web" of

interconnections has not already been unraveled? Why hasn't a

credible link to infection and Alzheimer's disease been suggested up to

this point in time? One reason might be that the SSPE

"Infection-Tangle-Dementia Triad" requires a special type of infection.

Only "inside the nerve" infections emulate the SSPE model. Such

infections are extremely rare. Rabies is an intraneuronal infection which

kills quickly.(ref 22) *Rabies and other rapidly progressing infections are*

"ineligible" for participation in the SSPE "Infection-tangle-Dementia

Triad" model. Chronic infections evolving over years are eligible for

such consideration. At this juncture, it is restated that short duration

SSPE infections never produce tangles (ref 23); the only SSPE infections which produce tangles are the long term infections. So it is necessary to identify a chronic and intracellular (intraneuronal) infection candidate to link Alzheimer's disease with other slow to evolve brain infections, in the SSPE tradition.

Chronic neuroborreliosis has recently been linked to individual cases of Alzheimer's disease.(ref 24 25 26 27) Observations in experimental primate neuroborreliosis by Fikrig and colleagues(ref 28) has established a category of so called "*paucibacillary*" infection in which the spirochetes are difficult to visualize in brain tissue. "Invisible" spirochetes are detectable by abundant spirochetal RNA in brain extracts. Indeed the "molecular signature" of borrelia pathogens in the primate neuroborreliosis model is so complete, that analysis of over 80 gene equivalents (Open reading frames) is possible in analysis of primate autopsy material. A bonus harvested from the monkey brain research is the ability to select out of the total 1.6 million nucleotides of borrelia DNA , *only the key regions* which are robustly present in Autopsy brains after experimental infection. DNA probes designed to emulate the positive findings in primate research have successfully

detected specific borrelia DNA sequences inside of the neurons of the Alzheimer's disease hippocampus . (ref 29) These In situ DNA hybridizations now provide a justification, based on the SSPE infection model, to apply the Triad of Infection-Tangle-Dementia to Alzheimer's disease. The paradoxes and enigmas of Alzheimer's disease are "untangled" by these models.

Hypothesis:

Neurofibrillary tangles in Alzheimer's disease are derived from the effects of *prolonged intraneuronal infection* with Borrelia species. Infectious agents which enter the cytoplasm of nerve cells persist in the axonal space, and destabilize the microtubular systems of the neuron. Transmission of infectious DNA across synapses spreads the infection from one nerve to another nerve, in a pattern which is reminiscent of the spread of Rabies virus. Nerves which are spared from neurofibrillary tangles might be explained by the lack of synaptic connections to the nerves which are infected. The progression of Alzheimer's disease from early stages in the entorhinal cortex and hippocampal regions to late stage disease with involvement of higher

cortical and neocortical brain regions might be explained by nerve to nerve transmission of infection across synapses.

A previously described mouse model for SSPE supports trans-synaptic transmission of measles virus from one nerve to another. (ref 32)

Earlier observations dating to 1996 based on the natural history of SSPE infection, have also lead to published discussions by other authors of trans-neuronal transmission of the SSPE viral agent. (ref 16)

Once a nerve is infected, enzyme homeostasis mechanisms are corrupted by the biochemistry of the invading microbial pathogen.

Hyperphosphorylation of healthy Tau protein is one consequence of intracellular infection. A toxic environment created by infection accelerates formations of paired helical filaments, which are the underlying structures of Alzheimer-type neurofibrillary tangles.

Ultimately the chronically infected tangle corrupted neurons die.

Evaluation of the hypothesis:

Verification of infectious DNA within the cytoplasm of tangle bearing neurons in Alzheimer's disease could be accomplished with pathogen specific DNA probes. Positive DNA hybridizations in the

cytoplasmic regions of tangle laden neurons would confirm intracellular infection. Human DNA is never present in the interphase neuron in any region of the cytoplasm.

Microinjection of healthy human neurons in tissue culture with whole cell extracts of living *Borrelia* spirochetes labeled with green fluorescent protein markers (GFPs) would offer an alternate independent method for verification of the microtubule destabilization mechanism. Electron microscopy of the microtubular system of neurons after Microinjection in infectious spirochetal extracts, would provide images of destabilization of the microtubules. Microtubular collapse is a necessary condition to precede the formation of the Alzheimer-type tangles.

Consequences of the Hypothesis:

Ratification of the neural infection pathway to neurofibrillary tangles in Alzheimer's disease would add an essential link to connect Alzheimer's disease with occult chronic intraneuronal infections. The "infection tangles" concept explains a specific pathway to nerve cell death and the origins of large numbers for NFT laden nerve cells in

Alzheimer's disease. Previous borrelia infection mechanisms to relate Alzheimer "amyloid" Plaques and the granulovacuolar bodies of Alzheimer's have been described.(ref 30,31) A three part "infection explanation" encompassing the genesis of NFT, plaques, and GVB in Alzheimer's disease provides immediate justification for aggressive antispirochetal therapies in early Alzheimer's disease, with the prospect of a possible cure.

Acknowledgements:

Research support for this work was provided from a Grant from the Turn the Corner Foundation, New York, New York, and from Institutional support from St Catherine of Siena Medical Center, Smithtown, New York.

References:

1. Avila, J. Lucas, J.J., Perez, M., et al, " Role of Tau protein in both physiological and pathological conditions", 2004, *Physiol. Reviews*, 84: 361-384.

2. Iqbal, K., Grundkd-Iqbal, I, "Discoveries of tau, abnormally Hyperphosphorylated tau and others of neurofibrillary degeneration: A personal perspective", 2006, J. Alzheimer Disease 9:219-42.
3. Tolnay, M., Probst, A., "Review: tau protein pathology in Alzheimer's disease and related disorders", 1999, Neuropathology. and Applied Neurology, 25:171-187.
4. Ikeda, K., Aliyama, H., Kondo, H. et al "Numerous glial fibrillary tangles in oligodendroglia of subacute sclerosing panencephalitis with neurofibrillary tangles", 1995, Neuroscience lett. 194:133-5.
5. Garg, R.K., "Subacute sclerosing panencephalitis" 2002, Postgrad. Med. Journal., 78: 63-70.
6. Paul-Barbosa, M.M., Brito, R., Silva, C.A., et al., "Neurofibrillary Changes in the cerebral cortex of a patient with subacute sclerosing panencephalitis (SSPE)", 1979, Acta Neuropathol (Berlin) 48: 157-60.
7. Gascon, G.G., Frosch, M.P., "Case 15-1998 A 34 year old woman with confusion and vision loss during pregnancy", 1998, New England Journal of Medicine, 338: 1448-1456.
8. Ortega-Aznar A., Romero-Vidal, F. J., Castellvi, J., " Adult onset subacute sclerosing panencephalitis: clinicopathologic findings in 2

new cases", 2003, Clin. Neurol., 22:110-8

9. Spillitini, M.G., Tolnay, M., Love, S. et al, "Microtubule associated protein tau, heparan sulphate and a-synuclein in several neurodegenerative diseases with dementia", 1999, Medicine 97: 585-94.

10. Ellison, D. Love, S., et al, "Neuropathology" , 2nd edition, Elsevier pub. 2004.

11. Kumanishi, T., Seuchi, I., "Subacute Sclerosing panencephalitis: immunohistochemical demonstration of measles virus antigens in Paraffin sections" , 1979, Acta Neuropathol 48: 161-63.

12. Gajdusek, D.C., "Unconventional viruses and the origins of Disappearance of Kuru", Nobel Lecture - December 13, 1976, <http://nobelprize.org/nobel-prizes/medicine/laureates/1976/gajdusek-lecture.pdf>

13. Jin, L., Beard, S. Hunjan, R., et al, "Characterization of measles virus strains causing SSPE: A study of 11 cases" 2002, J. Neurovirology 8: 335-44.

14. Baczko, K. Lampe, J., Liebert, U.G., et al "Clonal expansion of hypermutated measles virus in SSPE brain", 1993, Virology 197:

188-95.

15. Hadfield, M.G., Martinez, A.J., Gilmartin, R.C., "Progressive Multifocal Leukoencephalopathy with paramyxovirus-like structures , Hirano Bodies, and Neurofibrillary tangles", 1974 Acta Neuropathol. 27: 277-88.

16. Allen, I.V., McQuaid, S. McMahon, J., Kirk, J., McConnell, R., "The significance of measles virus antigen and genome distribution in the CNS in SSPE for mechanism of viral spread and demyelination", 1996, J. Neuropathol. and Exp. Neurol. 55: 471-80.

17. Lewandowski, E. Szpak, G.M., Lechowicz, W. , et al , "Ultrastructural changes in neuronal and glial cells in subacute sclerosing panencephalitis: correlation with disease duration" , 2001, Folia Neuropathol. 39: 193-202.

18. Mandybur, T.I., "The distribution of Alzheimer's neurofibrillary tangles and gliosis ins Chronic SSPE", 1990, Acta Neuropathol. 80: 307-10.

19. Mandybur, T.I., Nagpaul, A.S., Pappas, Z., "Alzheimer neurofibrillary changes in SSPE", 2004, Annals of Neurology 1: 103-7.

20. McQuaid, S., Allen, I.V., McMahon, J. et al, " Association of measles

virus with neurofibrillary tangles in SSPE: A combined in situ hybridization and immunohistochemical investigation", 1994, Neuropathol. Applied Neurobiol., 20: 103-110.

21. Iwatsubo, T., Hasegawa, M., Ihara, Y., "Neuronal and glial tau positive inclusions in diverse neurologic diseases share common phosphorylation characteristics" 1994, Acta Neuropathologica 88: 129-136.

22. Kristensson, K., Dastur, K., Manghani, D.K., et al" Rabies: Interactions between neurons and viruses: A Review of the history of Negri Inclusion Bodies", 1996, Neuropathol. and Applied Neurobiology 22: ` 179-189.

23. MacDonald, A.B.."Borrelia in the brains of patients dying with dementia"JAMA 256:2195-96.

24. MacDonald, A.B., Miranda, J.M., "Concurrent neocortical Borreliosis and Alzheimer's disease", 1987, Human Pathology 18: 759-61.

25. MacDonald, A.B., " Concurrent neocortical Borreliosis and Alzheimer's disease: Demonstration of a Spirochetal Cyst form",1988, Annals of the New York Academy of Sciences 539: 468-70.

26. Miklosy, J.M., Khalili, K., Gem, L., et al, "Borrelia burgdorferi persists in the brain in chronic lyme neuroborreliosis and may be associated with Alzheimer's disease", 2004, J. Alzheimer's disease 6: 639-49.

27. Narasimhan, S., Caimano, M.J., Liang, F.T., et al, "Borrelia burgdorferi transcriptomes in the central nervous system of non-human primates", 2003, PNAS 100:15953-58.

28. MacDonald, A.B., "In situ DNA hybridization study of granulovacuolar degeneration in human Alzheimer Autopsy neurons for Flagellin b transcriptomes of Borrelia burgdorferi", 2006, Alzheimer's disease and Dementia 2: (Suppl1): S207.

29. Lawrence, D.M.P., Patterson, C.E., Dorzio, J.L., Rall, G.F.,

"Pathogenesis of neurotropic viral infections; Mechanisms of

Neuron-Neuron Transmission of Measles Virus" ,1999, FoxChase

Cancer Center Bulletin,

http://www.foxchase.org/sci_report/1999/Rall.pdf#search=%22neurofibrillary%20tangles%20sspe%22

30. MacDonald, A.B., "Plaques of Alzheimer's disease originate from

cysts of *Borrelia burgdorferi*., 2006, 67:592-600.

doi 10.1016/j.mehy.2006.02.035

31. MacDonald, A.B., "Cystic *Borrelia* in Alzheimer's disease and in non-Dementia neuroborreliosis", 2006, *Alzheimer's and Dementia* 2:(Suppl 1): S433.

Elsevier Editorial System(tm) for Medical Hypotheses

Manuscript Draft

Manuscript Number:

Title: Alzheimer's Disease Braak Stage Progressions: Reexamined and Redefined as Borrelia Transmission through Neural Circuits

Article Type: FLA Full Length Article

Section/Category:

Keywords:

Corresponding Author: Dr. Alan B. MacDonald, MD

Corresponding Author's Institution: St Catherine of Siena Medical Center

First Author: Alan B. MacDonald, MD

Order of Authors: Alan B. MacDonald, MD

Manuscript Region of Origin:

Abstract:

Abstract:

Brain structure in health is a dynamic energized equation incorporating chemistry, neuronal structure, and circuitry components. The chemistry “piece” is represented by multiple neurotransmitters such as Acetylcholine, Serotonin, and Dopamine. The neuronal structure “piece” incorporates synapses and their connections. And finally circuits of neurons establish “architectural blueprints” of anatomic wiring diagrams of the higher order of brain neuron organizations. In Alzheimer’s disease, there are progressive losses in all of these components. Brain structure crumbles. The deterioration in Alzheimer’s is ordered, reproducible, and stepwise. Drs Braak and Braak have described stages in the Alzheimer disease continuum. “Progressions” through Braak Stages benchmark “Regressions” in Cognitive function. Under the

microscope, the *Stages of Braak* commence in brain regions near to the hippocampus, and over time, like a tsunami wave of destruction, overturn healthy brain regions, with neurofibrillary tangle damaged neurons **“marching”** through the temporal lobe, neocortex and occipital cortex. In effect the *destruction ascends* from the limbic regions to progressively destroy the *higher brain centers*. Rabies infection also “begins low and finishes high” in its wave of destruction of brain tissue. Herpes zoster infections offer the paradigm of ***clinical latency of infection inside of nerves before the “marching commences”***. Varicella zoster virus enters neurons in the pediatric years. Dormant virus remains inside the neurons for 50 to 80 years, Tissue damage late in life (“shingles”) demonstrates the “march of the infection” down neural pathways (“dermatomes”) as linear areas of painful blisters

loaded with virus from a childhood infection.

Amalgamation of Zoster with Rabies models produces a

hybrid model to explain all of the Braak Stages of

Alzheimer's disease under a new paradigm, namely

“Alzheimer's neuroborreliosis” in which latent borrelia

infections ascend neural circuits through the hippocampus

to the higher brain centers, creating a trail of

Neurofibrillary tangle injured neurons in neural circuits of

cholinergic neurons by transsynaptic transmission of

infection from nerve to nerve.

Sunday
Sept 17th, 2006

Dr Bruce Charlton
Editor in Chief
Medical Hypotheses

RE:
Manuscript submission
“Alzheimer’s Disease Braak Stage Progressions”
Reexamined and Redefined as Borrelia infection
Transmission through Neural Circuits”

Dear Dr. Charlton,

I submit for your consideration, the above captioned
Manuscript for publication in Medical Hypotheses.

The work is original, and has not been submitted
For publication elsewhere.

In the event that you find it acceptable for publication,
I agree to abide by all of the Copyright provisions of Elsevier Publishers.

Thank you very much for considering this manuscript.

With best wishes,

Alan B. MacDonald, MD
1 Franciscan Lane
Smithtown, New York 11787 USA
Email: inmacdonald@yahoo.com

Alzheimer's Disease Braak Stage Progressions:
Reexamined and Redefined as Borrelia
Infection Transmission through Neural Circuits

Alan B. MacDonald, MD
St. Catherine of Siena Medical Center
Department of Pathology
50 Rte 25 A
Smithtown, New York 11787, USA

Abstract:

Brain structure in health is a dynamic energized equation incorporating chemistry, neuronal structure, and circuitry components. The chemistry “piece” is represented by multiple neurotransmitters such as Acetylcholine, Serotonin, and Dopamine. The neuronal structure “piece” incorporates synapses and their connections. And finally circuits of neurons establish “architectural blueprints” of anatomic wiring diagrams of the higher order of brain neuron organizations. In Alzheimer’s disease, there are progressive losses in all of these components. Brain structure crumbles. The deterioration in Alzheimer’s is ordered, reproducible, and stepwise. Drs Braak and Braak have described stages in the Alzheimer disease continuum. “Progressions” through Braak Stages benchmark “Regressions” in Cognitive function. Under the

microscope, the *Stages of Braak* commence in brain regions near to the hippocampus, and over time, like a tsunami wave of destruction, overturn healthy brain regions, with neurofibrillary tangle damaged neurons **“marching”** through the temporal lobe, neocortex and occipital cortex. In effect the *destruction ascends* from the limbic regions to progressively destroy the *higher brain centers*. Rabies infection also “begins low and finishes high” in its wave of destruction of brain tissue. Herpes zoster infections offer the paradigm of ***clinical latency of infection inside of nerves before the “marching commences”***. Varicella zoster virus enters neurons in the pediatric years. Dormant virus remains inside the neurons for 50 to 80 years, Tissue damage late in life (“shingles”) demonstrates the “march of the infection” down neural pathways (“dermatomes”) as linear areas of painful blisters

loaded with virus from a childhood infection.

Amalgamation of Zoster with Rabies models produces a

hybrid model to explain all of the Braak Stages of

Alzheimer's disease under a new paradigm, namely

“Alzheimer's neuroborreliosis” in which latent borrelia

infections ascend neural circuits through the hippocampus

to the higher brain centers, creating a trail of

Neurofibrillary tangle injured neurons in neural circuits of

cholinergic neurons by transsynaptic transmission of

infection from nerve to nerve.

Introduction:

Staging concepts in discussions of the progression of Alzheimer's disease provide "scaffolds" for thinking about what is gained (neurofibrillary tangles, toxic tau proteins, Plaques, amyloid, granuolvacuolar bodies) and what is lost (neurons, synapses, brain mass, cognitive abilities, personal dignity and autonomy). The Braak six part staging system for neuropathologists (Ref 1) focuses on the time and space issues of the sequence of progression of injured neurons bearing neurofibrillary tangles in Alzheimer's autopsy brain tissues.

Neural Maps of diseased territories in the Alzheimer brain are elegantly illustrated in the Braak model. Autopsy brain studies from octogenarians demonstrate that, based on the *single parameter of tangles*, autopsy brains with tangles confined to small regions of the entorhinal cortex,

(proximate to the hippocampus) comprise Braak Stage 1.

Stage 1 patients are never demented. Brains with *widespread “tangle bearing”* neurons in the higher neocortex and occipital cortex regions are Stage 6. **Stage 6 patients are always demented.** Stages 2,3,4,5 in the Braak system are intermediary points in the journey from intact brain function to total incapacitation. A visual representation of the Braak Stages is provided in the artist’s depiction of Dr Braak’s original publications in Figures 1,2,3 .

Mapping studies of Neural circuits of the brain, spinal cord and peripheral nervous system by neuroscientists in the 21st century now utilize induced infections of neurons to determine “connections” in neural circuits. Signals from virus infected nerves show progressive “maps” of infection that correspond to the wiring diagrams of nerves in a

circuit. This is somewhat reminiscent of satellite assisted navigation systems used for global positioning systems in military applications. Microscopic “tracking “ of infections which are experimentally produced in animals and which “jump across synapses” actually identify all “connections” in a neural circuit without the need to “kill” any cells.

Transsynaptic transmission of “PseudoRabies virus” is an essential tool in mapping “ascending” and “descending” type neural circuits. For example, virus injected into the animal’s eye is “ tracked” in nerves leading to the visual centers of the brain. Virus injected into the animal’s stomach is tracked in multiple neural circuits (sympathetic and parasympathetic) back to the brain stem. Under the microscope, nerves which are connected in an “electrical circuit-like relationship” show the effects of virus inside their axon and soma regions; while “unconnected” adjacent

neurons show no visual “viral protein tracer” material.

PseudoRabies in the neuroscience laboratories capitalizes on the clinical experience with its lethal neurotropic namesake. Rabies infection in wild animals “ascends” to the brain via an “inside of the nerve” pathway from the bite site, through the spinal cord, upwards through the brain stem to the higher brain centers. Other models of intraneuronal infection, with documented categories of transsynaptic spread of infection to neurons in the brain are summarized in Table 1. .

Infections of the Borrelia type are from their inception inherently neurotropic. Image based evidence for Borrelia in either corkscrew, granular or cystic forms has appeared in the peer reviewed literature. Latency of Neuroborreliosis

in hamsters with laboratory induced brain infections was described in the last century. Animal brains actually kept *Borrelia* isolates from ticks alive for future laboratory study in antebellum times when no artificial culture media existed to support the *in vitro* growth of *Borrelia* spirochetes.

Recently, using the tools of *In situ* DNA hybridization of Alzheimer's disease brain tissues, additional image based evidence for residence of *Borrelia* inside of human brain neurons has been reported. (See Empirical Observation section of this document). A model has been offered, based on the model of intraneuronal infection of brain neurons in SSPE (subacute sclerosing panencephalitis) to provide a "cognitive link" between *chronic* "inside of the nerve viral infection " and the appearance of neurofibrillary tangles in chronically infected neurons (Ref 2). A similar sequence of events (i.e. Nerve infection with *borrelia* and formation of

Neurofibrillary tangles in infected nerves) has been postulated, based on the SSPE-Infection-Neurofibrillary tangle formation observations.

Hypothesis:

Herein is postulated that the transsynaptic transmission of borrelia infection along neural circuits from the entorhinal cortex to the neocortex and beyond is the de facto cause to explain both the sequence and topography of Braak's stages 1 through 6 in Alzheimer's disease. The initial brain infection by Borrelia is established. Infection remains latent and subclinical (in a manner analogous to the viral latency noted in Herpes Zoster infection of Dorsal root ganglionic Neurons). Activation of latent neuroborreliosis initiates neuronal injury and the formation of neurofibrillary tangles. Nerve to nerve transmission of borrelia infection across

synapses (mainly involving cholinergic neurons) results in a “neural circuit” infection. The consecutive spread of infection follows the Braak Stages 1-6 sequence.

Ascending infection in cholinergic neural circuits produces an “escalator effect”. The Escalator effect of infection in neural circuits explains the spatial (geographic) and chronological sequences on the Braak stages of Alzheimer’s disease.

Evaluation of the Hypothesis:

Trans-synaptic transmission of borrelia infection could be evaluated in laboratory animals by use of Green Fluorescent protein (GFP) labeled Borrelia strains injected into peripheral anatomic sites whose neural projections are already defined in the neural circuits of the brain.

Cholinergic neural circuits in the brains of laboratory

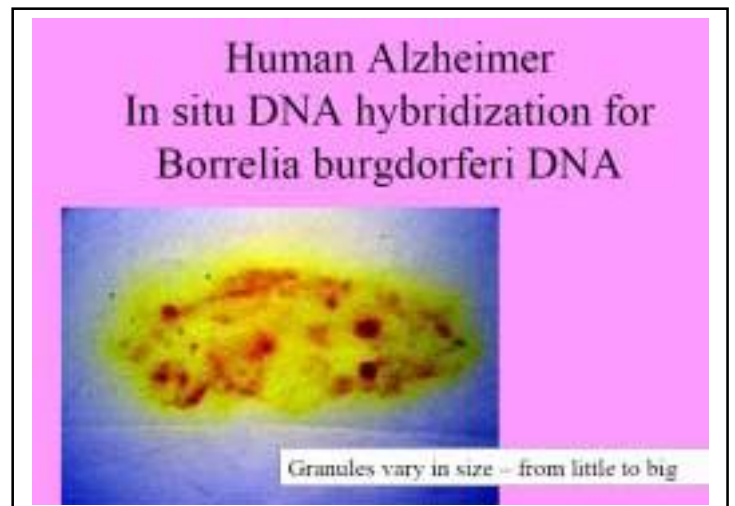
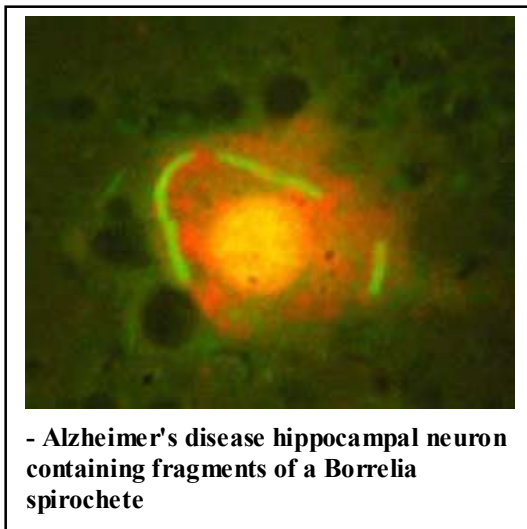
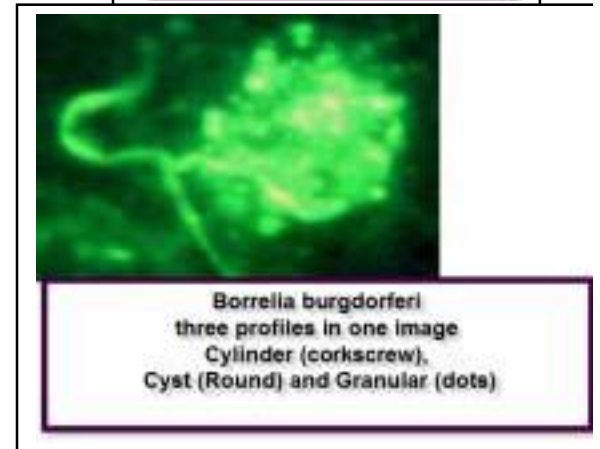
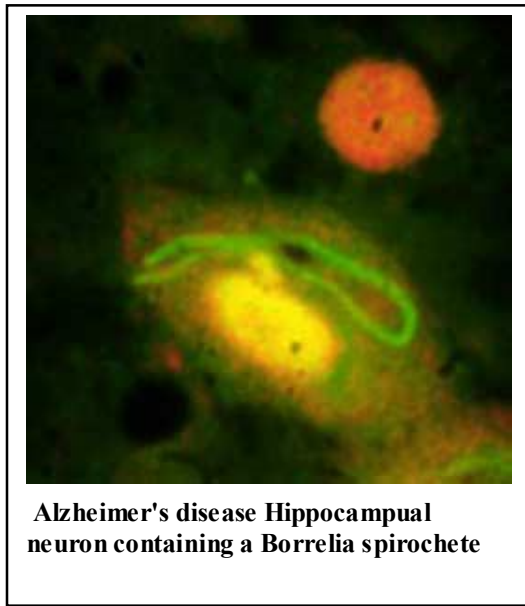
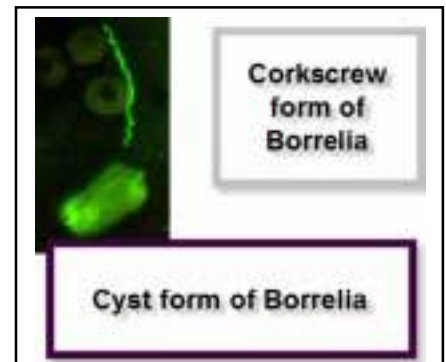
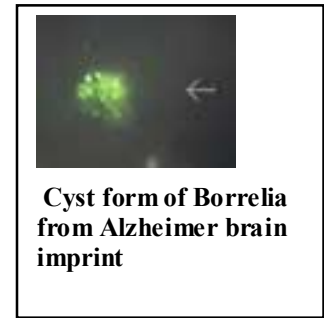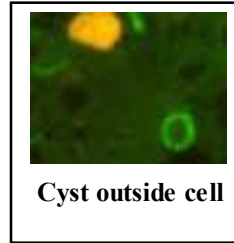
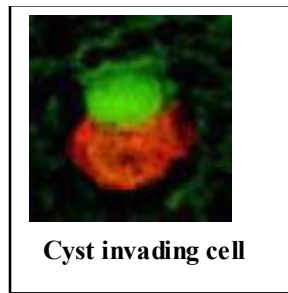
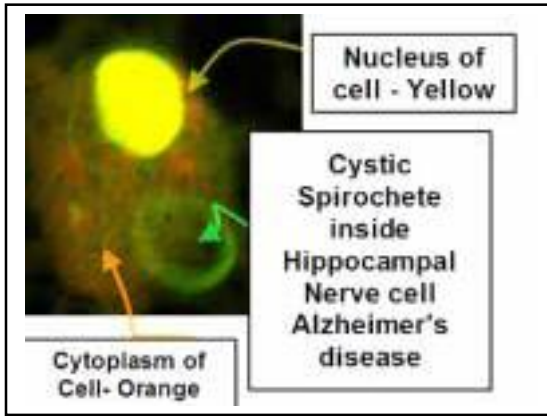
Animals (primates) could be evaluated for trans-synaptic transmission of GFP labeled *Borrelia* by surgical injection of the hippocampus neurons, with prolonged “incubation” and serial autopsy study of the brains.

Empirical Data:

Cocktails of single stranded DNA oligomeric probes and single molecular Beacons have succeeded in demonstrating profiles of *granular and cystic borrelia forms* in the cytoplasm of Alzheimer hippocampal neurons. Single strand DNA staining of Alzheimer’s disease neurons has demonstrated *cytoplasmic DNA staining sites in Alzheimer’s disease neurons*, which correspond to the profiles of *spirochetal filamentous, cystic, and granular Borrelia forms*.

If the “entrance portal” for borrelia infection of cholinergic neural circuits is indeed the hippocampus region, then the only remaining “missing piece” is evidence for Transsynaptic transmission of borrelia to the “higher centers” of the brain.

Empirical Data:



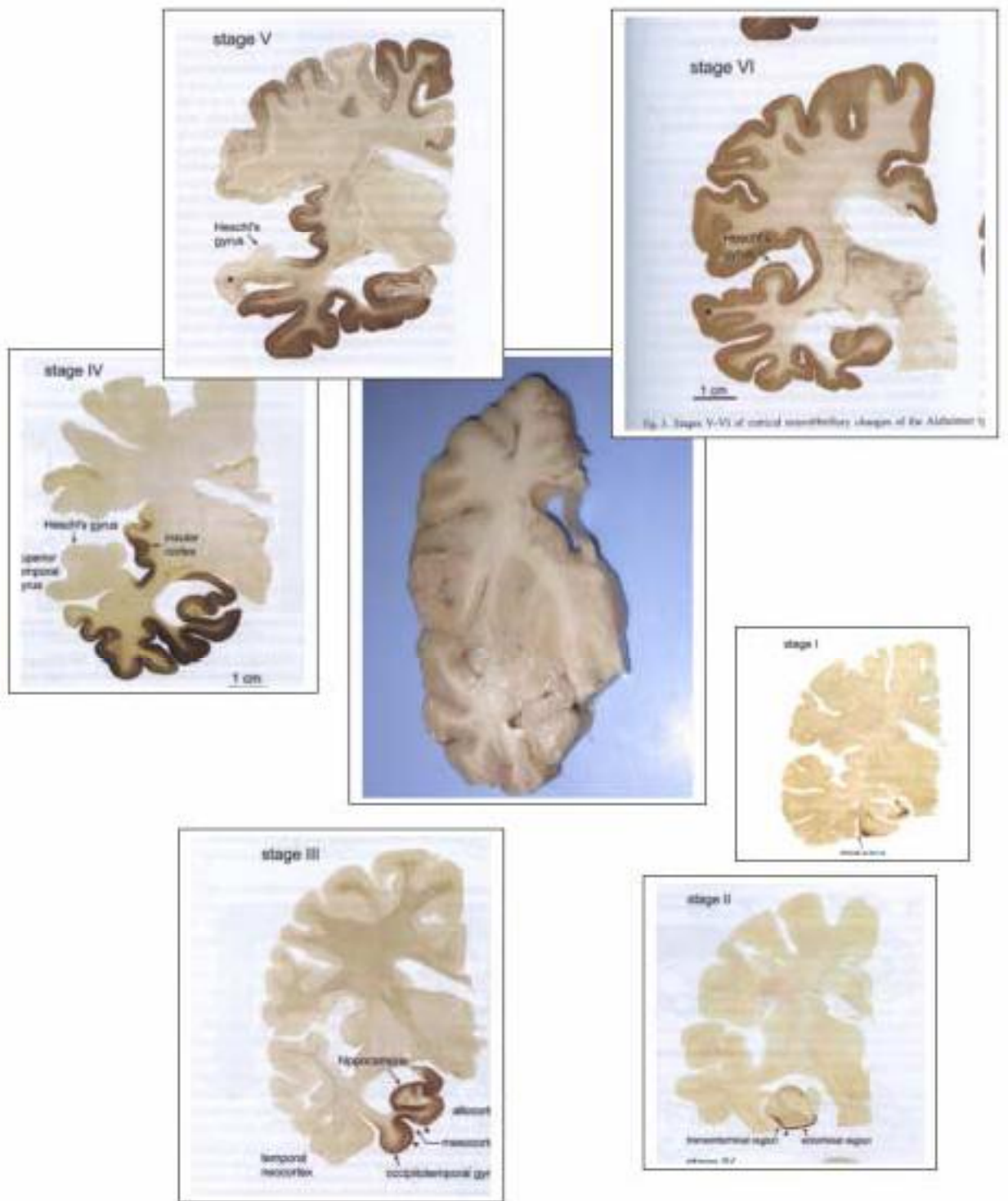


Figure 1 Braak Stages 1-6 Artist Composite from Original Manuscript by Dr Braak. Clockwise rendering of the "Ascending" dissemination of injured neurons with Neurofibrillary Tangles in Alzheimer's Disease.

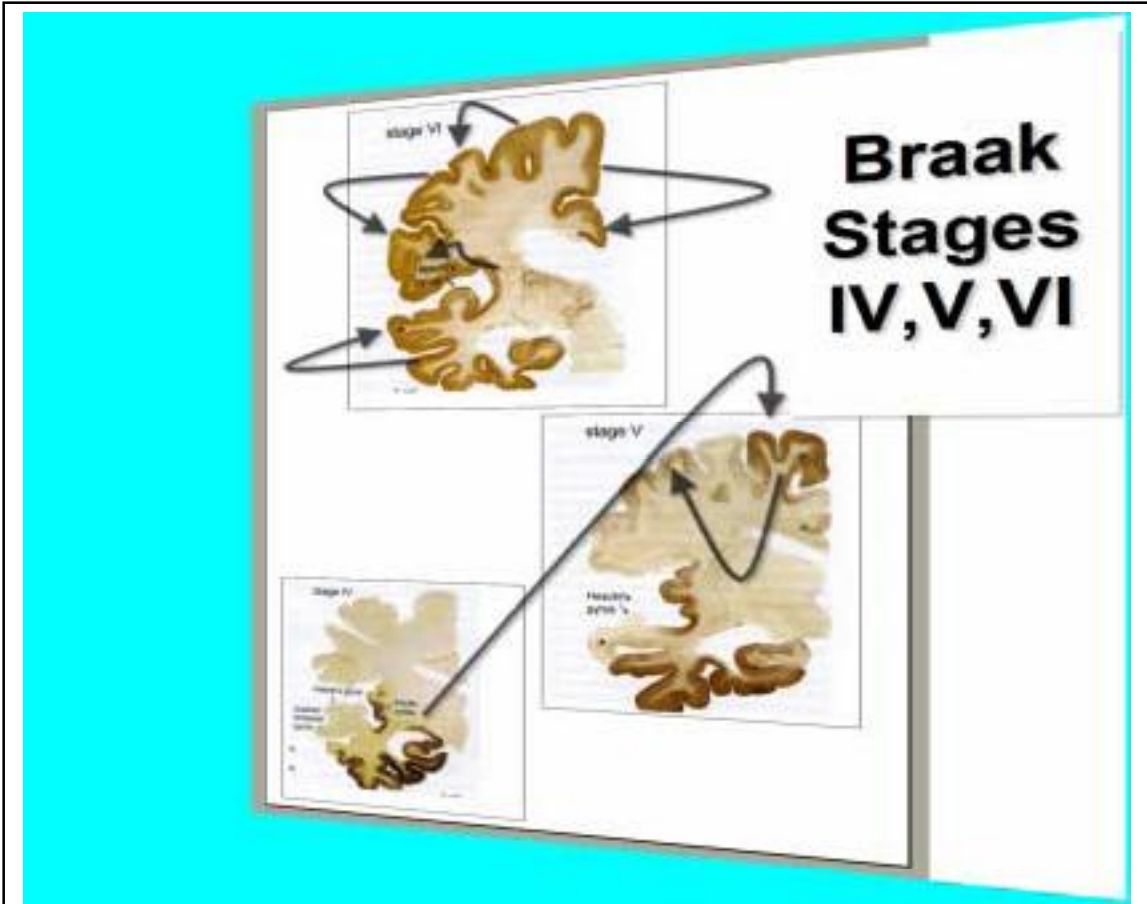
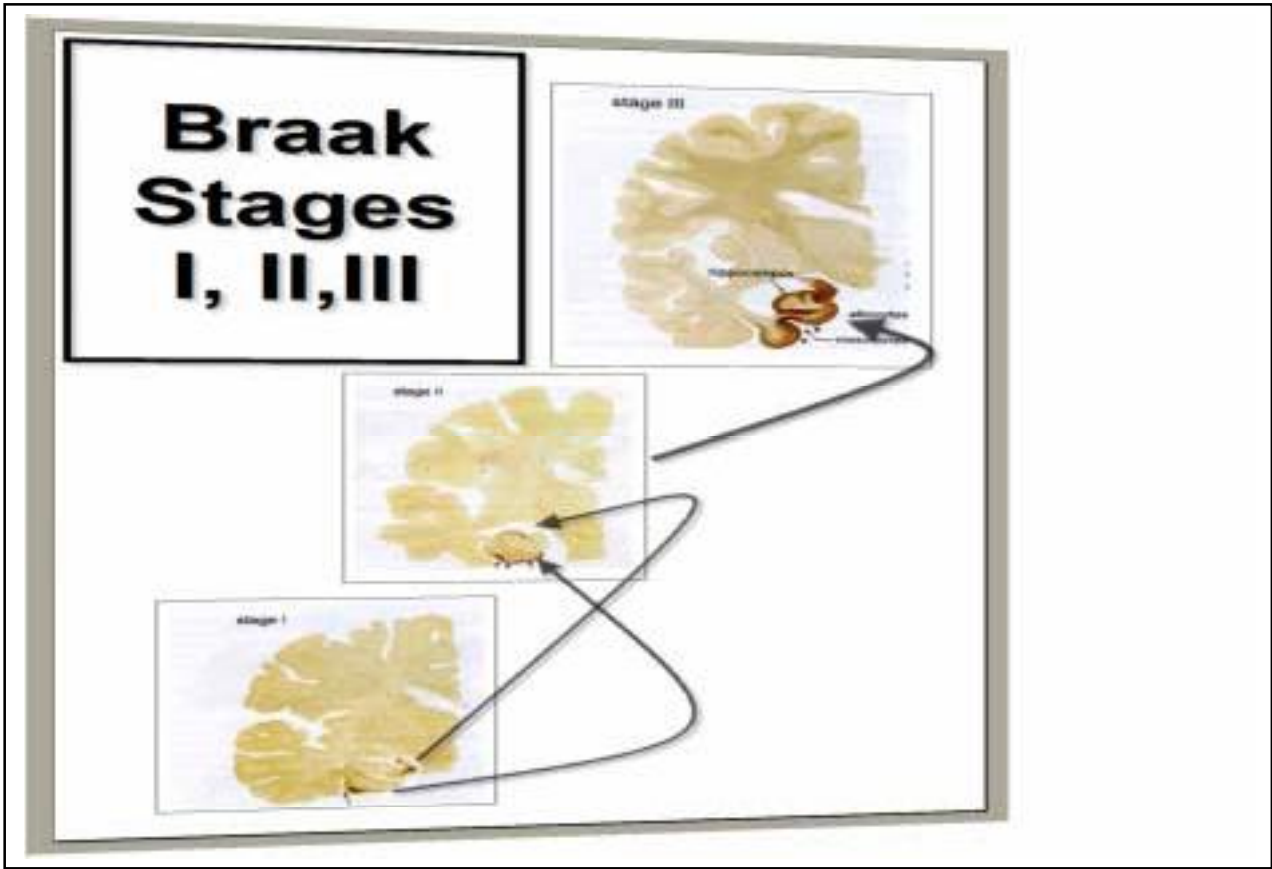


Figure 2 Braak Stages 1-6 of evolution of Alzheimer's disease. Artist Rendering.

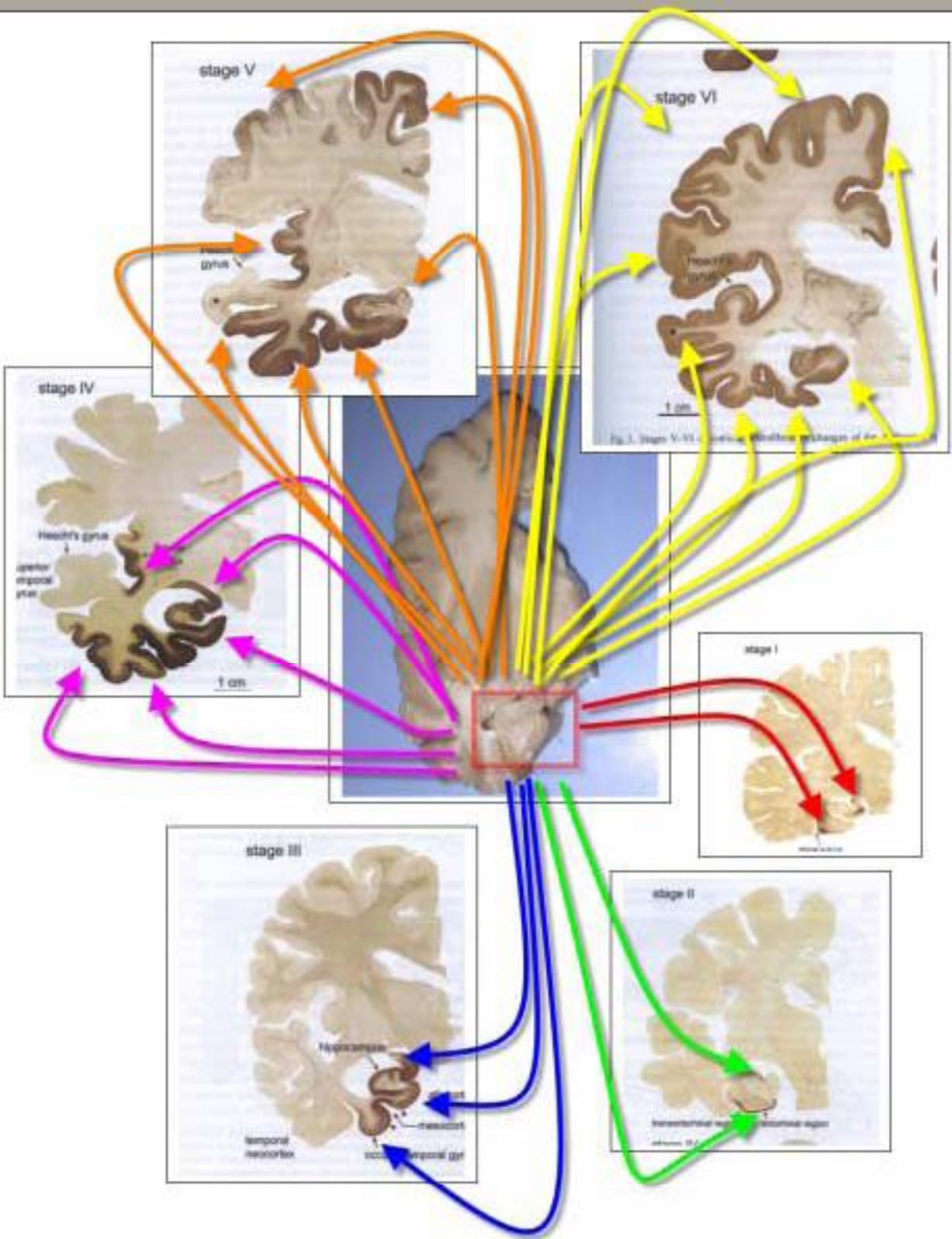


Figure 3: The Evolution of Braak stages 1-6. Neurons with Neurofibrillary Tangles initially confined to the Box area in Stage 1 , progressively disseminate along cholinergic circuits indicated by arrows in Braak Stages 2-6. Artist Rendering.

Infections Inside of Neurons , Schwann cells or Glia

(*** documents Transsynaptic transmission of Infection)

*****Rabies Virus (Ref 3,4)**

*****Pseudorabies Virus (Ref 5,6,7)**

*****Herpes Zoster (Varicella Zoster) Virus (Ref 8,9)**

*****Herpes Simplex Virus (Ref 10)**

Measles Virus

*****Variant Measles (SSPE Agent) Virus (Ref 11,12)**

*****West Nile Virus (Ref 13)**

Poliomyelitis Virus

*****Adenovirus (Ref 14)**

*****Simian B Virus (Ref 15,16)**

Canine Distemper Virus

*****Influenza Virus H5N1 (Ref 17)**

Tick Borne Encephalitis virus

*****Prion Agent of Creutzfeldt Jacob (Ref 18)**

*****Prion Agent of Transmissible Mink Encephalopathy (Ref 19)**

Prion Agent of Variant CJD (Mad Cow Disease)

Kuru Agent

*****Scrapie Agent (Ref 20)**

Leprosy (Mycobacterium Leprae)

*****Listeria infection of Trigeminal Nerve in Mouse (Ref 21)**

*****Treponemal Spirochetes (Oral) via Trigeminal Nerve to Brain (Ref 22)**

*****Vesicular Stomatitis Virus (Ref 23,24)**

Various Mosquito borne encephalitis viruses

Consequences of the Hypothesis:

Ratification of transsynaptic transmission of borrelia along cholinergic neural circuits of the brain from the hippocampus to higher neocortical sites (Braak stages IV,V,VI for Alzheimer's disease) would prove an infectious causation for this epidemic dementia. In this paradigm shift, traffic in neural circuits would necessarily be redefined to encompass both neurochemical agents and intraneuronal infectious agents in Alzheimer's disease.

Reinvention of the "flagship" of the Tauopathy complex of neurodegenerative diseases, namely Alzheimer's disease, as an infection that develops in cholinergic neural circuits, would then provide new opportunities for the improvement of our understanding of the mechanisms of diseases in the other members of the Tauopathy family. Reclassification of Tauopathies as infections would open the door for infection

targeted therapeutic interventions to eradicate many neurodegenerative diseases.

Acknowledgements:

This research was supported by a grant from the Turn the Corner Foundation, New York, New York and from institutional support from the St Catherine of Siena Medical Center, Smithtown, New York.

References:

1. Braak, H, Rub, U., Schultz, C. et al, “Vulnerability of Cortical Neurons to Alzheimer’s and Parkinson’s Diseases” in Alzheimer’s Disease: A Century of Scientific and Clinical Research, Perry G. editor, 2006 IOS Press, pages 35-44.
2. MacDonald, A.B. “ Alzheimer’s neuroborreliosis with Transsynaptic transmission and neurofibrillary tangles derived from intraneuronal spirochetes”, Medical Hypotheses, 2006, in press.
3. Dietzschold, B., Schnell, M., Koprowski,H., “Pathogenesis of Rabies”, Current Topics in Microbiology and Immunology, 2005, 292:45-56.
4. Jackson, A., “Rabies Virus Infection: an Update”, J. Neurovirology, 2003, 9:253-8.

5. Pomeranz, L.E., Reynolds, A.E., Hengartner, C.J.,
“Molecular Biology of Pseudorabies Virus: Impact on
Neurovirology and Veterinary medicine”, *Microbiol.
Mol. Biol. Rev.* , 2005, 69: 462-500.

6. Pickard, G.E., Smeraski, C.A., Tomlinson, C.C., et al,
Intravitreal injection of the attenuated pseudorabies
virus PRV Bartha results in infection of the hamster
suprachiasmatic nucleus by only retrograde
transsynaptic transport via autonomic circuits”, *J.
Neuroscience*, 2002, 22: 2701-2710.

7. Card, J.P., Levitt, P, Enquist, L.W., “Different
patterns of neuronal infection after intracerebral
injection of two strains of PseudoRabies virus”, *J.
Virology*, 1998, 72: 4434-41.

8. Cramer, S.S., Sigal, A., Hamilton, R. et al,
“Leukoencephalitis due to varicella zoster virus:
Report of a Case and a review of clinical features”, J.
Contemporary Neurology, 1996 1: 2.

9. Rostal, S.W., Olson, K., McDougal, J., et al,
“Transsynaptic spread of Varicella Zoster virus
through the visual system”, Human Pathology, 1989,
20:174-79.

10. Dehal, N.S., Dekaban, G.A., Krassioukov, A.V.,
et al.,”Identification of Renal sympathetic
preganglionic neurons using transsynaptic transport of
herpes simplex type 1 virus”, Neuroscience, 1993,
56:227-40.

11. Cathomen, T., Mrkic, B., Spehner, D., et al, "A matrix-less measles virus is infectious and elicits extensive cell fusion: consequences for propagation in the brain", *EMBO Journal*, 1998, 17: 3899-3908.

12. Lawrence, D.M.P., Patterson, C.E., Gales, T.L., et al. , "Measles virus spread between neurons requires cell contact but not CD46 expression, Syncytium formation or Extracellular virus production", *J. Virology*, 2000, 74:1908-1918.

13. Shresta, B., Gottlieb, D., Diamond, D., "Infection and Injury of neurons by West Nile Encephalitis virus", *J. Virology*, 2003, 77:13203-13.

14. Kinoshita, N., Mizuno, T., Yoshihara, Y., "Adenovirus-mediated WGA gene delivery for

- transsynaptic labeling of mouse olfactory pathways”,
Chem. Senses, 2002, 27:215-223
15. Gosztonyi, G., Falke, D., Ludwig, H., “Axonal transsynaptic spread as the basic pathogenetic mechanism in B virus infection of the nervous system”, J. Med. Primatol., 1992, 21:42-3
 16. Breshears, M.A., Black, D.H., Ritchey, J.WW.,” Construction and in vivo detection of an enhances Green Fluorescent protein expressing strain of Samirline herpesvirus 1 (SAHV-1), Archives of Virology, 2004, 148:311-327.
 17. Klopfleisch, R., Wener, O., Mundt, E., et al, “Neurotropism of highly pathogenic avian Influenza

- virus A/Chicken/Indonesian/2003 (H5N1) in experimentally infected pigeons (*Columbia livia f. domestica*), *Vet. Pathol.* 2006, 43:463-70.
18. Mabbott, N.A., MacPherson, G.G., “Prions and their lethal journey to the brain”, *Nature Reviews Microbiology*, 2006, 4: 201-211.
 19. Bartz, J.C., Kincaid, A.E., Bissen, R.A.,”Retrograde transport of transmissible mink encephalopathy within descending motor tracts”, *J. Virology*, 2002, 76: 5759-68.
 20. McBride, P.A., et al.,”Early spread of Scrapie from the gastrointestinal tract to the central nervous

system along fibers of the splanchnic and vagus nerves”, J. Virology, 2001, 75:9320-27.

21. Jin, Y., Dons, L., Kristensson, K.,”Neural route of Cerebral *Listeria monocytogenes* murine infection: role of immune response mechanisms in controlling bacterial”, Infection and Immunity, 2001, 69: 1093-1100.

22. Riviere, G.R., Riviere, K.H., Smith, K.S.,”Molecular and immunologic evidence of oral *Treponema* in the human brain and their association with Alzheimer’s disease”, Oral Microbiology Immunology, 2002, 17: 113-118.

23. Greenstein, J.I., Baron-van Evercooren, A.G., Lazzarini, R.A., et al, "Infection of the Central nervous system produced by R 1 Vesicular Stomatitis virus", *Lab. Invest.*, 1981, 44: 487-95.
24. Lundh, B., "Spread of Vesicular Stomatitis virus along visual pathways after retinal infection in the mouse", *Acta Neuropathologica* , 79: 395-401.

Elsevier Editorial System(tm) for Medical Hypotheses

Manuscript Draft

Manuscript Number:

Title: Transfection "Junk" DNA- a link to the Pathogenesis of Alzheimer's Disease?

Article Type: FLA Full Length Article

Section/Category:

Keywords:

Corresponding Author: Dr. Alan B. MacDonald, MD

Corresponding Author's Institution: St Catherine of Siena Medical Center

First Author: Alan B. MacDonald, MD

Order of Authors: Alan B. MacDonald, MD

Manuscript Region of Origin:

Abstract:

Transfection “Junk” DNA – A link to the Pathogenesis of Alzheimer’s disease?

Alan B. MacDonald, MD

St. Catherine of Siena Medical Center

Department of Pathology

50 Rte 25 A

Smithtown, New York

USA

11787

Telephone 1-631-862-3764 (voice)

Fax 1-631-862-3863

Residence 1-631-724-1335

Address: Residence :

1 Franciscan Lane

Smithtown, New York, 11787

Affiliation:

Employee : Pathology and Laboratory Consultants of Long Island LLC
Medical Staff, St Catherine of Siena Medical Center

Research Grant Support :

Turn the Corner Foundation, New York, New York

Research Affiliation:

Harvard University McLean Hospital Brain Bank
of Harvard Medical School, Boston, Mass

Conflicts of Interest:

None

Abstract:

A transfection product incorporates in one molecule of human DNA , an inserted segment of DNA from another species. This communication addresses the hypothesis that a novel variation of the theme of transfection, namely “junk transfection” for which no protein product and no RNA is transcribed, might offer insights into the pathogenesis of Alzheimer’s disease. It is hypothesized that spirochetal DNA gains access to the intracellular compartment of nerve cells during the subclinical latency phase of neuroborreliosis and chemically combines with human DNA. A previously reported Molecular interrogation of Alzheimer’s disease autopsy tissues has yielded novel DNA sequences containing the 11 q human chromosome and a short piece of the *Borrelia burgdorferi* Flagellin B DNA. Although the usually encountered transfection product bundles an entire nonhuman gene within it, this model proposes that shorter inserts into the human genome constitute “junk transfection” because no protein is derived from them. Junk transfusions would offer an important new cognitive model for the detection of occult infections as the root causes for the Tauopathies, which are degenerative neurological disorders, including Alzheimer’s disease.

Introduction:

Transfection is the human subset of Lateral Transfer of DNA. Horizontal (or Lateral) DNA transfers occur in many prokaryotic to eukaryotic cell systems, and may be transient or permanent events in the life of the organism.(1.)

Lateral DNA transfer is epitomized by the transfection events in human retroviral infections (HIV/AIDS).(2.) Bacterial to human transfection has been benchmarked in the *Agrobacterium tumefaciens* to HeLa tissue culture model of Citovsky and colleagues. (3.) Structural similarities of the vector plasmid of *A. tumefaciens* with the linear plasmids of *Borrelia burgdorferi* offer a conceptual bridge to allow for consideration of *Borrelia* to human transfection to occur.(4.)

Hypothesis/theory:

Transfection of the ordinary type in controlled circumstances in the research laboratory is facilitated by commercially available kits. Various methods (viral vectors, electroporation, chemical catalysts) intrude foreign DNA into the human cytoplasmic/nuclear compartment. Chemical linkage of human DNA with the non human DNA may occur as random events , or , with the participation of specific restriction endonucleases, may show a site specific integration within the human genome.

A molecular interrogation of Alzheimer's disease brain tissues was undertaken based on the model of primate experimental neuroborreliosis, using the polymerase chain reaction method. Flagellin B transcriptome sites were designed for the nested primer oligonucleotides, based on the success of these molecular probes in the primate model. Seven of ten Alzheimer's disease cases produced sharp bands of the intended target size of 500 base pairs. Nucleotide sequences analysis demonstrated a fusion of Borrelia flagellin B DNA with a short piece of human Chromosome 11q. In a supercomputer search of all known DNA sequences, matches were identified for human chromosome 11q (241 out of 137 million bases for chromosome 11) and Borrelia flagellin DNA (22 out of 1011 bases). These seven novel sequences are now deposited in the national Gene Banks for the USA, Europe, and Japan.(Sequences identifiers = gi 73427170, gi75914674 to gi 75914679) BLASTn searches disclose remarkable structural homologies in this group of seven (RID:1131018016-21957-186797320278.BLASTQ3) , for which the term "Junk Transfection" is proposed. It is hoped that these novel sequences will eventually be useful as a molecular signature for Alzheimer's disease.

Evaluation of the Hypothesis:

A larger scale study with the identical experimental methodology is needed to corroborate the detection of “junk transfection” DNA . There are no previous publications known to exist for which no measurable product occurs following the insertion of foreign DNA to produce a Transfection product . If “silent transfection” is occurring in the laboratory, or in nature, then only DNA sequence analysis will verify it. It is hoped by way of predictive speculation, that the “Junk transfection” DNA will find a niche in molecular biology lexicons and and practice. Many examples exist in nature for “noncultivable” microbes, which are so fastidious that they refuse to grow in liquid culture media in the microbiology laboratory. *Treponema pallidum*, the spirochetal agent of syphilis will not grow in the microbiology laboratory. By analogy, the ‘Junk transfection DNA’ concept is a model to establish a conceptual link between a pathogenic microbe in diseased tissue, which is recalcitrant of in vitro culture attempts and is also “inert” in the usual transfection scenario, in which DNA via RNA produces a measurable protein product in the transfected cells.

Word Count = 826 words

References:

1. Bushman, Frederick, 2002, Lateral DNA Transfer mechanisms and Consequences
Cold Spring Harbor Laboratory Press, cold Spring Harbor , New York.
2. Bushman, F., Lewinski, M., Ciuffi, A., et al. , 2005
, Genome- wide Analysis of Retroviral DNA Integration,
Nature Reviews Microbiology, 3: 848-58.
3. Kunik, T.,Tzfira, t., Kapulnik, Y., Gafni, Y., Dingwall, C., Citovsky, V., 2001,
Genetic transformation of HeLa Cells by *Agrobacterium*, Proceedings of the
National Academy of Sciences, 98: 1871-76.
4. Chaconas, G, 2005, Hairpin telomeres and genome plasticity in *Borrelia*:
all mixed up in the end, Molecular Microbiology, 58(3), 625-635.

Word count = 927